

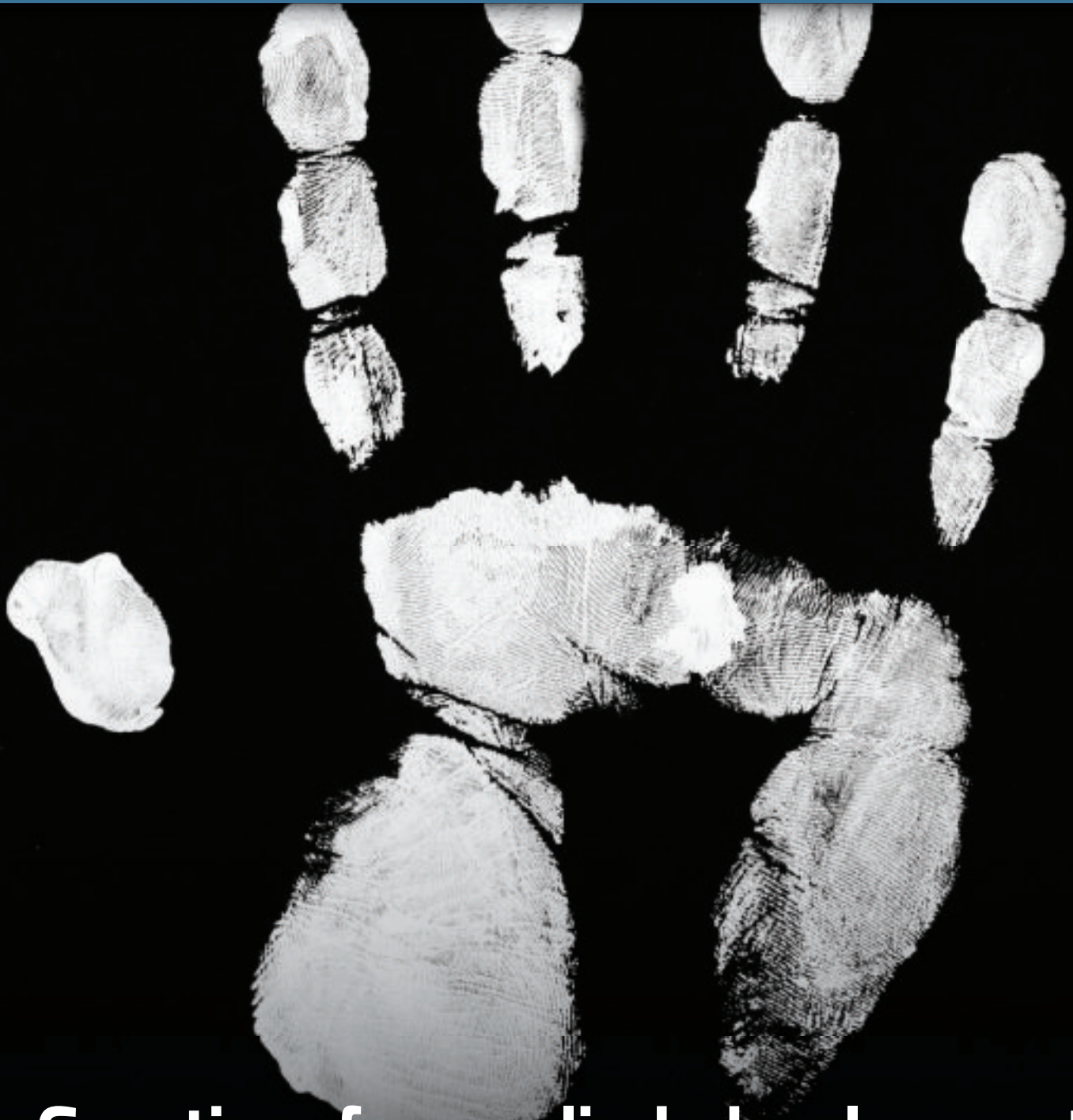# ezine ifssh

CONNECTING OUR GLOBAL HAND SURGERY FAMILY

Journal highlights

Executive news

Member society updates



## Genetics of upper limb development

NEW CLASSIFICATION  
FOR CONGENITAL  
ANOMALIES

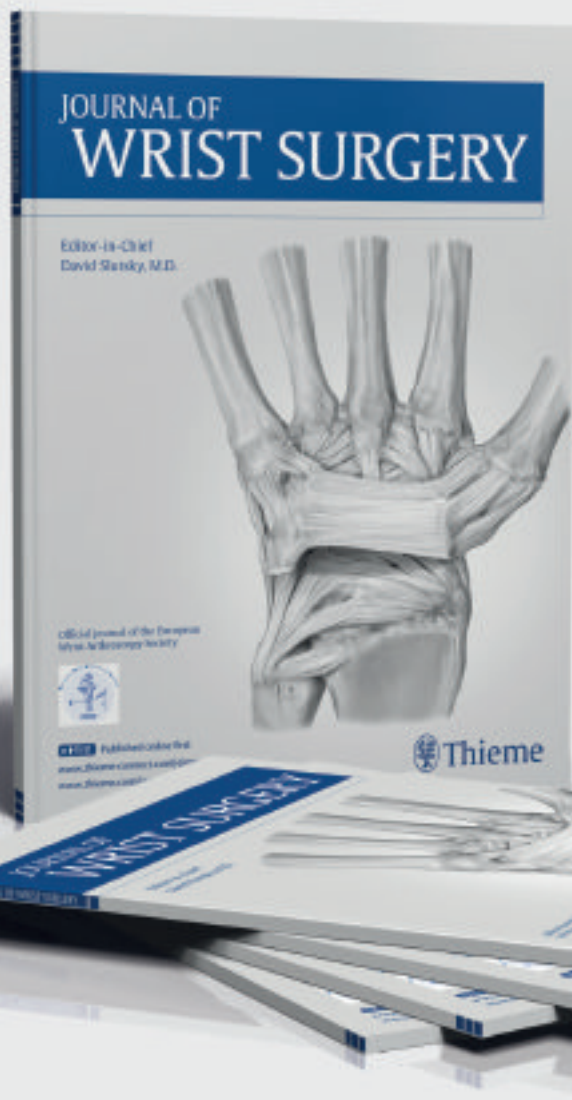DART THROWING  
MOTION OF THE  
WRIST

HAND THERAPY:  
MALLET FINGER  
SPLINTING



# NEW SUBSCRIBERS: Take 20% off

A quarterly peer-reviewed periodical covering all aspects of wrist surgery and small bone surgery of the hand



## Journal of Wrist Surgery

Editor-in-Chief: D. Slutsky

2014/Volume 3/4 issues p.a./ISSN 2163-3916

### USA and Canada

Individuals: \$182 \$146

Institutions: \$492

Please contact [customerservice@thieme.com](mailto:customerservice@thieme.com)

For institutional licenses, please contact [esales@thieme.com](mailto:esales@thieme.com)

### Mexico, Central and South America

Individuals: \$198 \$158

Institutions: \$510

Please contact [customerservice@thieme.com](mailto:customerservice@thieme.com)

For institutional licenses, please contact [esales@thieme.com](mailto:esales@thieme.com)

### Europe, Africa, Asia, Australia, and New Zealand

Individuals: €139 €111

Institutions: €371

(Please add handling charges: €36)

Please contact [customerservice@thieme.de](mailto:customerservice@thieme.de)

For institutional licenses, please contact [eproducts@thieme.de](mailto:eproducts@thieme.de)

### Bangladesh, Bhutan, India, Nepal, Pakistan, and Sri Lanka

For subscription rates in INR, please contact

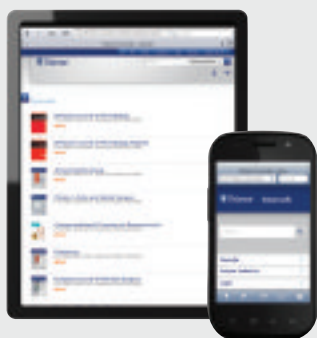[customerservice@thieme.in](mailto:customerservice@thieme.in)

## SUBSCRIBE NOW AND STAY UP-TO-DATE IN 2014

Visit [www.thieme.com/jws](http://www.thieme.com/jws) in order to subscribe or renew your subscription.

Take full advantage of your individual subscription by registering online at <https://www.thieme-connect.de/products>

- Individual subscribers get **free online access to current and back issues** of their journal(s)
- Advanced online access for select journals via the **eFirst service**
- Compatibility with **smartphones and mobile devices**
- Advanced search across our entire library of journals



**ORDER TODAY**



<http://www.thieme.com>

Special introductory rates are only valid for new subscribers and are limited to the first year of subscription. Only qualified professionals and students are eligible for individual subscriptions. Orders from individuals must include the recipient's name and private address, and be paid by private funds.



Become a fan at [www.facebook.com/thiemepublishers](http://www.facebook.com/thiemepublishers).



Follow us @ThiemeNY



**Thieme**



# Contents

## 4 Editorial

By Professor Ulrich Mennen, editor of the IFSSH ezine  
Photo Gallery

## 5 Executive news

Newsletter from the Secretary-General:  
Marc Garcia-Elias

## 6 Member society updates

- American Association for Hand Surgery
- American Society for Surgery of the Hand
- British Society for Surgery of the Hand
- Federation of South American Societies for Surgery of the Hand
- Singapore Society for Hand Surgery
- Slovak Hand Surgery Society
- Spanish Society for Hand Surgery
- Swiss Society of Surgery of the Hand
- Turkish Society of Hand and Upper Extremity Surgery

## 14 Committee reports

- IFSSH Scientific Committee on Congenital Conditions: Classification of Congenital Hand and Upper Limb Abnormalities
- IFSSH Scientific Committee on Genetics in Hand Surgery: New Insights on Upper Limb Development: Digitising the Hand

- IFSSH Scientific Committee on Anatomy and Biomechanics: Wrist biomechanics and Instability - Wrist dart-throwing motion updated

## 30 Hand therapy

Mallet fingers around the globe: Does one best method for immobilisation and mobilisation exist?  
Julianne Howell

## 37 Research roundup

Basic science of bone healing

## 38 Special feature

## 40 Pioneer profiles

Douglas Lamb  
Luis Gómez Correa

## 42 Journal highlights

Tables of Content from leading journals such as The Journal of Wrist Surgery, The American Journal of Hand Surgery, Journal of Hand Surgery Asian Volume, Journal of Hand Surgery European Volume and the Journal of Hand Therapy.

## 46 Upcoming events

List of global learning events and conferences for hand surgeons and therapists



# Important information for Delegates

**The IFSSH Charter states that “Each constituent society will be represented by one Delegate”.**

Many delegates are not aware of their important functions and responsibilities. The IFSSH cannot function without the active involvement and participation of each Delegate. Please be reminded that the duties of delegates include the following:

- Delegates represent the members of their societies
- Delegates form the IFSSH Council, which is the governing body of the federation
- Delegates are therefore obliged to attend the IFSSH Annual Council Meetings
- Delegates are responsible to inform the members of their societies about the federation activities, e.g. Congresses, the IFSSH website
- Delegates are required to share/forward relevant correspondence to their society members e.g. the IFSSH ezine, the official electronic magazine
- Delegates are expected to help identify able and willing members of their societies to serve as Scientific Committee Members when

requested by the IFSSH President

- Delegates need to ensure that their society annual dues are paid-up
- Delegates are encouraged to acquaint themselves with the bylaws of the IFSSH in order to be able to make a meaningful contribution as member of the IFSSH Council
- Delegates will be requested to recommend Pioneers from their societies to be submitted to the Nominating Committee (NB: Pioneers are only members who have made a significant contribution)

From the above it should be clear that the role and function of a Delegate is not only an honourable one, but carries with it active participation and accountability.

The 2014 IFSSH Delegates' Council Meeting will be held at 12h00, Thursday 19th June at the FESSH Congress venue in Paris, France.



*See you there!*

**Ulrich Mennen**

Editor: IFSSH ezine

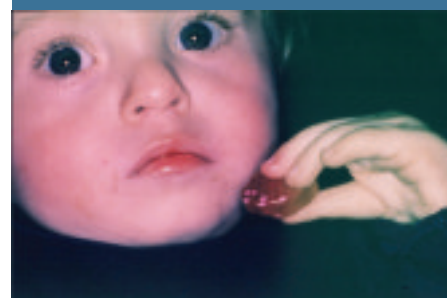Past-President: IFSSH

[www.ulrichmennen.co.za](http://www.ulrichmennen.co.za)

## IFSSH CONTRIBUTOR PHOTO GALLERY

Dear colleague,  
You are invited to send interesting photos from your practice which you would like to share with the other members of our profession.

Please add one short sentence to describe the photo which should be of good quality. Your name and country will be added to acknowledge your contribution. Send your contributions to:  
[editor@ifssh.info](mailto:editor@ifssh.info)



*‘Sweet’ result of an index finger pollicisation - Ulrich Mennen, South Africa*

**IFSSH disclaimer:** The IFSSH ezine is the official mouthpiece of the International Federation of Societies for Surgery of the Hand. The IFSSH does not endorse the commercial advertising in this publication, nor the content or views of the contributors to the publication. Subscription to the IFSSH ezine is free of charge and the ezine is distributed on a quarterly basis. To subscribe, please **click here**. Should you wish to support this publication through advertising, please **click here**.

### IFSSH ezine editorial team:

**Editor:** Professor Ulrich Mennen (Immediate Past President of the IFSSH)

**Deputy Editor:** Professor Michael Tonkin (President of the IFSSH)

**Publication coordinator:**

Marita Kritzinger (Apex ezines)

**Graphic Designer:** Andy Garside

SUBSCRIBE TO THE  
ezine  
**ifssh**  
FOR FREE

# Message from the Secretary-General: Marc Garcia-Elias

## Dear friends

It seems as if it was yesterday, but more than one year has passed since we last met in India. One full year, and yet, the warm colors of Delhi keep haunting us. If you had the wonderful privilege of being there, you will probably understand what I mean. India was definitively fabulous... period!

...but it's time to move ahead: the annual meeting of the Federation of European Societies for Surgery of the Hand (FESSH) is around the corner (\*), and believe me, if Paris alone is always worth the trip, this time it will be more than worth, it will be a unique opportunity,...and I mean it.

In most travel agencies it is customary to say that a trip to Paris is always a good idea. I agree. It was an excellent idea to bring the 2014 FESSH meeting back to Paris. Last time was in 1996. Eighteen years! That is too much time for a city like Paris not to be visited by an International Federation of hand surgeons. Let's thank FESSH for giving us such a long awaited opportunity.

They say that June is a great time to visit Paris. Warm weather and cozy gardens to enjoy the summer sunshine, however, should not be the only reasons for you to book your flight tickets. I don't know why, but I suspect that our French colleagues, with the support of the Council of FESSH, are

about to give us more than that. I suspect that we all will be offered the most amazing gift one may get in such occasions: the best scientific program wrapped by delightful social activities ...a gift that will be kept in our minds for a long time. Paris, indeed, knows how to treat visitors.

I know that the French event is not our meeting, and that perhaps I am trespassing a red line here. I know that it is not up to the Secretary-General of the IFSSH to advertise another federation's meeting, but I do not care. The Société Française de Chirurgie de la Main, organisers of the FESSH meeting, are also members of our Federation and, as a rule, any initiative by an IFSSH member aimed at improving the quality of hand care delivery will always meet our sympathy. So, let's give a big hand to our French friends.

There is a second reason for me to bring this meeting up to your attention; a practical reason, if you will. We have scheduled our annual Delegate's Council meeting during the FESSH congress. It will start at room 242B of the Palais des Congrès de la Porte Maillot, sharp at noon on Thursday, 19th of June, 2014. All National Delegates are expected to attend that meeting. As in the past, doors will be open to all of those who want to hear about what is going on in our Federation. Among other things,



we will discuss, and hopefully approve, our new bylaws, the ones that will allow us a new legal status. We will also analyse what has been done so far and what needs to be done. Several educational projects are going on, how can we enhance their success? What about our next 2016 congress in Buenos Aires? What about beyond that? Yes, if our Federation was a sailing ship, Paris would be our lighthouse. Let's trust what Paris has to teach us, and beyond that...full-speed ahead!

*Yours truly,*

**Marc Garcia-Elias**

*Secretary-General of the IFSSH*

(\*) see <http://www.fessh2014.com/en/welcome>

# Member society updates

## American Association for Hand Surgery

### Highlights of AAHS 2014 Annual Meeting in Hawaii

Under the direction of program chairs, Dr Steve Moran and Dr Joy MacDermid, the AAHS Annual Meeting held January 2014 was as spectacular academically as it was in its beauty in the setting of the island of Kauai, Hawaii. The morning only sessions had spectacular courses in all areas of what is new in hand therapy and hand surgery. Highlights included several sessions on wide awake hand surgery. The improvement in outcomes obtained by seeing active movement in flexor tendon repair before the skin is closed is now evident with decreased rupture rates, decreased tenolysis rates, and more confidence in doing true active movement postoperatively. Substituting epinephrine vasoconstriction for the tourniquet has removed the need for sedation and permitted moving carpal tunnel surgery out of the main operating room into the clinic or office for much greater convenience of the surgeon and the patient. Relative motion extension splints for functional early return to work after extensor tendon repair should now be considered by all. Relative motion flexion splints are revolutionizing boutonniere management. Gentian violet for chronic paronychia is a simple solution that works.

The AAHS Annual Meeting is

attractive in that it happens every year in a warm beautiful place in January. It also always happens at the same time as the American Society for Microsurgery and American Society for Peripheral Nerve meetings for enhanced educational opportunity. Serious contributions by therapists in panels and courses in the AAHS meeting is rewarding. The relaxed atmosphere with nightly social events permits plenty of time for information exchange between expert and novice.

The 2015 AAHS Annual Meeting being organized by Drs Mark Baratz, Tom Hughes, and Christine Novak, a joint meeting with the British Society for Surgery of the Hand, will be held January 21-24, 2015 at the Atlantis on Paradise Island in the Bahamas. Visit <http://meeting.handsurgery.org> for more information.

**Dr Donald Lalonde**  
*AAHS Past President*

## American Society for Surgery of the Hand (ASSH)

The 69th Annual Meeting of the American Society for Surgery of the Hand will be held in Boston, Massachusetts from September 18-20th. For the past several years, ASSH has invited the members of a hand society from another country to participate in the meeting as our International Guest Society. This year, we are honored to host the Brazilian Hand Surgery Society as our International Guest Society. We look forward to meeting with our colleagues from Brazil and from around the globe. For travel information, visit our website.

As always, the ASSH meeting will feature the highest quality medical education and research findings for attendees, and this year, we are also focusing on medical outreach. The meeting's theme, "Hands Helping Hands" celebrates our most basic goals as physicians – to serve.

Additionally, ASSH is co-hosting two international meetings in 2015. The first will be with SSHS in Singapore in February 25 - 28, 2015. The second will be a combined meeting with ASSH



and JSSH in Maui, Hawaii, March 29 – April 1, 2015.

We hope that you will join us, either in Boston or at our meetings with SSHS and JSSH, but we also realize that, between the challenges of travel and the need for high quality education, it is imperative that we build tools beyond face-to-face meetings to facilitate education. ASSH recently launched an online learning community called Hand-e ([hande.assh.org](http://hande.assh.org)), filled with peer-reviewed videos, articles and more. This community is free for ASSH members and ASSH international members, and it will soon be available to international non-member surgeons at an adjusted subscription rate designed to make the tool affordable for physicians of all countries.

Visit [www.assh.org](http://www.assh.org) to learn about many other opportunities, like the ASSH Textbook of Hand and Upper Extremity Surgery and our outreach programs.



## British Society for Surgery of the Hand

Although an informal dining club had existed since 1952 (The Hand Club), the British Society for Surgery of the Hand (BSSH) owes its true origins to a more serious group founded in 1956 and rather facetiously named “The Second Hand Club”. This group, led by Guy Pulvertaft and Graham Stack, organized regular meetings to discuss hand surgery, arranged instructional courses, and at a very early stage looked outside the United Kingdom to forge wider friendships and collaboration in the emerging specialty.

The Club flourished for 12 years, then developed a more formal constitution, adopting the title it has today. An important stimulus for the formation of these successive groups was the spread of hand surgery across two major specialties. It embodied a desire in orthopaedic and plastic surgeons, at that time, to join forces

and cooperate in the creation of a merged specialty based on friendship and shared expertise. The fruitful cooperation between surgeons from orthopaedic and plastic surgery backgrounds is a strong theme of the Society. BSSH maintains an even-handed balance between the parent specialties in its Officers and Council members.

The objectives of BSSH are “to promote and direct the development of hand surgery and to foster and coordinate education, study and research in hand surgery”. Although hand surgery is not a separate specialty in the UK, many surgeons devote all, or most, of their time to hand surgery. Current membership of BSSH is 725.

In 1992, BSSH instituted a national system of fellowships in hand surgery, after training in one of the two parent specialties. Each of these “Interface” posts provides training in both orthopaedic and plastic surgery



elements of hand surgery. Educational approval is given by the BSSH through the "Training Interface Group for Hand Surgery" which regulates the training, in conjunction with the national training committees in orthopaedic surgery and plastic surgery. Between 1992 and 2014, over 200 surgeons completed this programme.

BSSH holds a two or three day scientific meeting each Autumn and in most years also holds a Spring scientific meeting. Some meetings are held jointly with the British Association of Hand Therapists and with other National Hand Societies. For many years regular instructional courses were run alongside meetings and in 1999 a regular cycle of formal advanced courses was set up, covering the whole field of hand surgery every 3 years. This has been very successful and has considerable international appeal. These biannual two-day courses run in Manchester over a three-year cycle and cover the entire spectrum of surgery of the hand. Typically each course has 120-150 participants, 40% of whom are from other countries, mainly in Europe.

Following on from this, BSSH in collaboration with the University of Manchester has since 2007, established a Diploma in Hand Surgery, using the content of the courses as the basis for a syllabus. Surgeons in the fellowship programme take a modular course of face-to-face tuition with tutorials and projects. There are internal assessments at the workplace and a final external examination.

The Journal of Hand Surgery is the official journal of the Society, evolving from the "Proceedings of the Second

Hand Club", through "The Hand", edited by its founder Graham Stack, to its present form. It was initially linked to the American Journal of the same name and more recently adopted as the official European journal. It has long been established as one of the foremost publications on the subject. The Journal is run through a committee with European and wider international representation. It is the official journal of the FESSH, the Belgian Hand Group, the Netherlands Society for Surgery of the Hand, the Société Française de Chirurgie de la Main, the Swedish Society for Surgery of the Hand and the Swiss Society for Surgery of the Hand. An annual donation of £35,000 (€42,000) is made to FESSH from the income of the Journal.

From its earliest days the Society has recognized the vital roles played by physiotherapists and occupational therapists in the treatment of patients, and close, highly supportive links with those disciplines have been established and maintained through professional collaboration, joint meetings and educational activities, and sponsorship in both directions.

BSSH is one of the founder members of the Healing Foundation, a national fundraising charity championing the cause of people living with disfigurement and visible loss of function, by funding research into pioneering surgical and psychological healing techniques.

In collaboration with the Healing Foundation, an Academic Post in Hand Surgery has been funded by the BSSH. The sum of £500K will be spent to support a University Chair, which will set up a national network to research

the treatment and outcomes of many conditions.

BSSH has played an active role in the development of international organizations promoting hand surgery; from the outset, the BSSH included representatives from the whole of Ireland.

Formation of the International Federation of Societies for Surgery of the Hand was first proposed at a meeting of The Hand Club in 1965. Graham Stack was the second Secretary General and Douglas Lamb the third President. The Society has also played an active role in the formation and growth of the Federation of European Societies for Surgery of the Hand (FESSH), successfully hosting the 2006 Congress in the UK.

To support research education and training BSSH awards several prizes, bursaries and grants, totalling £85,000 each year.

BSSH is involved in overseas work; since 2010 groups of surgeons anaesthetists hand therapists and nurses, funded by BSSH, have been visiting the Holy Spirit Hospital in Sierra Leone to treat the local population and train local staff. The ultimate goal is self-sustainability.

For the future, BSSH continues to promote hand surgery nationally and internationally, and seeks to match the rapid growth in the number of trained surgeons dedicated to the specialty with increased opportunities for purpose-designed training programmes crossing speciality boundaries.

**David Shewring**

*BSSH Delegate to IFSSH/FESSH  
davidshewring@me.com  
www.bssh.ac.uk*



## Federation of South American Societies for Surgery of the Hand

The Federation of South American Societies for Surgery of the Hand has produced an open access book on Hand Surgery in Portuguese.

You are welcome to follow the link here [http://fedscm.com/book\\_chapters](http://fedscm.com/book_chapters)

## Singapore Society for Hand Surgery

Hand surgery in Singapore has been an independent specialty, with a training track separate from orthopaedics and plastic surgery training, since 1998. In the last few years, with the introduction of the American residency system for specialty training locally, Hand Surgery Residency Programs have been established in Singapore with three institutions currently accredited to run the program.

Even prior to hand surgery becoming an independent specialty, the Singapore Society for Hand Surgery (SSHS) was established in 1982 as a forum for hand surgeons in Singapore to share their knowledge and experience, particularly in the management of hand conditions arising from leprosy, rheumatoid arthritis and a high incidence of industrial accidents. Over the years, the membership of our society has risen greatly, owing to an increase in the number of hand surgeons in Singapore, occupational therapists with an interest in hand therapy, as well as our overseas associate members, many of whom had spent some time working with various hand surgical units in Singapore.

Apart from the annual scientific



**Friends of Singapore Hand Surgery at the Post 2013 IFSSH Congress Tour in Rajasthan, India.**  
**Seated (L to R): Andrew Chin (President Singapore Society for Hand Surgery); Tan Ter Chyan (Singapore); Lim Beng Hai (Singapore).** **Standing (L to R): Kalvis Pastars (Latvia); Sandeep Sebastin (Vice President Singapore Society for Hand Surgery); Peng Yeong Pin (Singapore); Aivars Tihonovs (Latvia); Pasi Paavilainen (Finland); Aymeric Lim (Singapore); Shalimar Abdullah (Malaysia); Yrjana Nietosvaara (Finland); Janis Krustins (Latvia).**

meeting and comprehensive hand review course, SSHS organizes various courses and lectures by invited speakers throughout the year, some of which are attended by regional participants. Additionally, SSHS also contributes to the continuing medical education of hand surgeons and hand surgical trainees by organizing regular teaching seminars.

In 2013, our annual scientific meeting was a combined meeting with various overseas hand surgical societies – the Joint Singapore-Malaysia-Finland-Estonia-Latvia Hand Surgery Societies Meeting (incorporating the 22nd Comprehensive Review Course in Hand Surgery and Annual Scientific Meeting) was held from 28th February 2013 to 2nd March 2013. The event allowed generous exchange of ideas



**Singapore's first Pioneer in Hand Surgery, Prof Pesi B Chacha receiving the Pioneer Award from Prof Ulrich Mennen (Immediate Past president of IFSSH) at the 12th Triennial Meeting of the IFSSH at New Delhi, March 2013.**

among hand surgeons from different regions. Apart from lectures on congenital hand surgery by our invited international speaker, Professor Simo Villki, all participants were treated to a whole range of lectures touching on all aspects of hand surgery delivered by surgeons from all the participating societies. And in true Singaporean style, all participants were also treated to a variety of delectable local and international cuisine during the conference period.

Apart from the combined meeting, SHSS also hosted distinguished surgeons from overseas in 2013. Professor Fuminori Kanaya presented a dinner lecture on 'Motor and Sensory Nerve Differentiation' in March 2013 while Professor Scott Kozin discussed 'The Surgeon's Role in Providing Pinch and Grip' in July 2013.

Our annual scientific meeting this year was held in January 2014 with Professor Alexander Shin and Professor Tu Yuan-Kun as our invited international speakers. Apart from the hand review course, sessions dedicated to brachial plexus surgery were conducted by local and international faculty.

Meanwhile, the society has started preparation for our 2015 annual scientific meeting – the Inaugural Combined Scientific Meeting of Singapore Society for Hand Surgery (SSHS) and American Society for Surgery of the Hand (ASSH). The dates for this meeting have been tentatively set from 26th February to 1st March. The society would like to use this opportunity to invite surgeons to this event which is expected to be a truly enriching experience.



**Teodor Kluka, M.D., PhD.**  
*Email: [tkluka@unlp.sk](mailto:tkluka@unlp.sk)*



**Drahomír Palenčár,**  
*SHSS Vice President*



**Silvia Vajcziková,**  
*SHSS President*

## Slovak Hand Surgery Society

This history of hand surgery in Slovakia reflects the historical developments in Slovakia itself: the Slovak Republic was founded on 1st January 1993 and became a successor state following the dissolution of Czechoslovakia. Similarly, the hand surgery group was established as a combined "Czech and Slovak Hand Surgery Society", entering the IFSSH in 1993, followed by the foundation of the Slovak Hand Surgery Society (SHSS) on 1st January 1998.

Most of the credit for creating the Slovak Hand Surgery Society has to be given to the founding members and members of the Steering Committee: Jozef Janovic, Teodor Kluka and Jaroslav Ciganak. These three doctors also served on the first Slovak Hand Surgery Society Committee, whose members were Jozef Janovic (Chairman), Teodor Kluka (Secretary), Jaroslav Ciganak, Ladislav Kostal and Drahomir Palencar, along with Peter Kovar as the Auditor.

Influential surgeons in the development of hand surgery in Slovakia include A/Prof Jozef Janovic, A/Prof Jozef Fedeles and A/Prof Stefan Guzanin.

The first Hand Surgery Congress in Slovakia took place in 1996 at the High Tatra Mountains. The SHSS has

since organised numerous hand surgery congresses, presenting successes in microsurgery (Kluka, Palencar), distraction and external fixation (Guzanin, Ciganak, Kluka) and reconstructive plastic surgery (Palencar, Kluka). Technical literature includes the historical Hand Surgery Atlas (Simun, 1980) and more recent titles such as External Minifixation in Hand Injuries (Ciganak, 1998) and Flexor Apparatus Surgery (Bansky, 2006).

Hand surgery training is organised by the Slovak Medical University in pre-attestation preparation for plastic surgery, during which participants take courses in hand surgery. There is no current certification for hand surgery as a speciality.

In 2013, the SHSS officers elected were Silvia Vajcziková (President), Drahomír Palenčár (Vice-President) and Teodor Kluka (Secretary).

The 10th Slovak Congress of Hand Surgery will be held in Tále from 2-3 October, 2014. For further information, email: [ozhippokrates@gmail.com](mailto:ozhippokrates@gmail.com).

**Teodor Kluka, M.D., PhD.**

*Email: [tkluka@unlp.sk](mailto:tkluka@unlp.sk)*

*Drahomír Palenčár, SHSS Vice President*

*Silvia Vajcziková, SHSS President*

## Spanish Society for Hand Surgery

In February 1969, the first assembly of surgeons with a special interest in hand surgery was held in Zaragoza. This was so, thanks to the organisation of Dr Alfredo Quintana and with the collaboration of Dr Pulvertaft, Dr Vainio, Dr Tubiana and Dr Souquet as invited guest professors. A few months later, on 11th May 1969, the Spanish Society for Hand Surgery (SECMA) was founded in Zaragoza with only 29 members and under the leadership of the new president Dr Enriquez de Salamanca. At present, SECMA has a total number of 380 members (310 full members, 19 associated members, 25 international members, 26 honour members).

**New Board of the SECMA.** The new board of the Spanish Society was constituted during the last national meeting, held in Mallorca in May 2013 and its members are: Dr Miguel del Cerro (President), Dr Angel Ferreres (Vice-President), Dr Pilar Pradilla (General Secretary), Dr Luis Aguilera (Vice-Secretary), Dr Gabriel Celester (Treasurer), Dr Roberto S. Rosales (International Delegate), Dr Fernando Corella and Dr Pedro J. Delgado (Editors of the Ibero-American Journal of Hand Surgery), Dr Marta Guillen and Dr Joaquim Casañas (Council of the web side and communications).

**SECMA Foundation.** In 2014, the SECMA Foundation was established with the purpose of sponsoring the SECMA instructional courses, the best scientific paper and posters at our national meeting, the ASSH travelling fellowship award and all those activities related to research and teaching in the hand surgery field. This



*VI Congress of the Moroccan Society for Surgery of the Hand, Marrakech March, 22nd 2014. SECMA was the guest society. From the left to the right: Dr Ferreres (Vice President of the SECMA), Dr Rosales (International Delegate of SECMA), Dr Fnini (President of the Moroccan Society), Dr Pradilla (General Secretary of the SECMA), and Dr Cuadros (Past President of the SECMA).*

project was started in 2011 by Dr D. Fernando García de Lucas, who was the previous President of the SECMA, and finished by Dr Miguel del Cerro, the present President.

### SECMA & RICMA (The Ibero-American Journal of Hand Surgery).

The new online version of the "Revista Iberoamericana de Cirugía de la Mano (RICMA)", the Ibero-American Journal of Hand Surgery, has been presented recently. The new editors, Dr Fernando Corella and Dr Pedro J. Delgado, have carried out a tremendous task in designing a new electronic journal with an application for smart phones and tablets. We hope that in a short period of time, we may get our journal indexed. <http://revistaiberoamericanamano.org/>

**SECMA & IFSSH.** All the members of the SECMA are proud of the election of Dr Marc García Elías, outstanding member of our society, as General Secretary of the IFSSH.

**SECMA & FESSH.** The Spanish Society has always been working



*Magazine cover of the "Revista Iberoamericana de Cirugía de la Mano", the Ibero-American Journal of Hand Surgery with the support of the Hand Societies of Spain (SECMA), Argentina (AACM), Brazil (SBCM), Portugal (SPOCMA), Uruguay (SCPRE-Hand Section) and Venezuela (SVCM).*



closely with all the councils of the FESSH. A special mention must be made of Dr Angel Ferreres (Vice President) and of Dr Enrique McKenney (Previous International Delegate), as examiners in the European Board Diploma for the last years. Besides, following the recommendations of Dr Bruno Battiston, we have selected the required delegates in the Hand Trauma Committee. Finally, the city of Santander won the bid for the FESSH congress, which is to be held in 2016, with Dr Piñal as president.

**SECMA & The JHSE.** Recently, two members of our society have been added to the Journal of Hand Surgery (European volume) editorial committee: Dr D. Francisco Piñal, as one of the editors, and Dr D. Roberto S. Rosales as member of the editorial board.

**SECMA INSTITUTIONAL COURSES.** SECMA offers a two-day institutional instructional course every year, with lectures and lab cadaver sessions. This year, the course will take

place in Madrid under the direction of Dr D. Pedro J. Delgado on 24-25th April. Last year, the Spanish Society sponsored a new instructional course on Clinical Research Methodology in Hand Surgery. That one-day course, directed by Dr RS Rosales approached the clinical design, level of evidence, the use of patient reported outcome instruments and data analysis using the IBM SPSS Statistics.

**SECMA AND OTHER HAND SURGERY SOCIETIES.** The Spanish Society will collaborate as guest society in the Moroccan Hand Society Meeting in Marrakech on 22-23rd March 2014, and in the Portuguese Hand Society Meeting in Lisbon, in April 2014. Finally, the SECMA will be the guest society at the ASSH Meeting in Seattle, in 2015.

On behalf of the SECMA, I thank the IFSSH for the opportunity to present this updated news report of our society.

**RS Rosales, MD, Ph**  
(International Delegate of the SECMA)



**RICMA website, the electronic version of the "Ibero-American Journal of Hand Surgery": Free and open-full access at the following link: [www.revistaiberoamericanamano.org](http://www.revistaiberoamericanamano.org)**

## Swiss Society of Surgery of the Hand


### A brief history of Hand Surgery in Switzerland

*In fact, whatever manual, intellectual, cultural or spiritual activity each of us has devoted his life to, at the time of death, the individual is nothing; what he has achieved, however is everything.*

This is one of the last sayings of Claude E. Verdan, a genius pioneer in Hand Surgery, who influenced not only the national but also international scene in Hand Surgery. This most remarkable surgeon founded together with 50 General Surgeons the Swiss

Society of Surgery of the Hand on November 12th, 1966 in Lausanne.

During the following years this society grew to over 214 ordinary and extraordinary members (2014) and also



became part of the FESSH (1990, first delegate, Daniel V. Egloff, Lausanne) and IFSSH (1983, first delegate, Henry Nigst, Basel). A council of 9 members including an administration office is in charge to take care of the daily business of the society as well as to take positions in the political processes concerning the medical care in Switzerland. An annual congress is organised by the president.

In 1988, Hand Surgery was acknowledged as sub-speciality by the Swiss Medical Association (FMH). A recognition as a speciality on its own was given by the Federal Council in 2007. Another 6 years of certification



process and political struggle passed until the accreditation as a fully acknowledged speciality by the Swiss Medical Association (FMH) was completed. Trainees who completed a structured und verified postgraduate training may then use the title "Handchirurgie FMH" - a title which is recognized in most European countries. The official postgraduate training with this new accreditation will start in October 2014.

## Training of a Hand Surgeon in Switzerland

The new official training starts with a common trunk of two years of General Surgery completed by an examination of surgical basics. After passing this exam the trainee can enter the specialized training in Hand Surgery and in Surgery of peripheral Nerves. This training takes 4 years in at least 2 different institutions and finishes with an oral and written examination. Passing this exam and fulfilling a defined logbook, the trainee receives the Swiss Hand Diploma (FMH certificate).

Another way to become a Hand Surgeon is by entering the specialist training after completing the training as a General, Plastic, Pediatric or Orthopedic Surgeon. The achievement of this rather long education results in two diplomas acknowledged in Europe.

## Politics

Being a specialist in Switzerland you are allowed to perform certain surgeries restricted to the specialist category and you are rewarded with better payment rates compared



to surgeons without a certificate. Ongoing political discussions now try to cut these rates down in order to use the money for the general medical practitioners who slowly become a rare species. Therefore, there will be a lot of political work for the society and its council to keep a fair remuneration for a long education.

Furthermore, the society's main responsibility is to maintain a high standard in medical education and Hand Surgery training – a task we fulfill with great enthusiasm and joy. Multifactorial reasons such as more intellectual information and more technical skill requirements (microsurgery, arthroscopy and soon to be robotic surgery) to learn with shortening the time spent in training (resident work restrictions) and generational differences (balanced lifestyle) challenge all but Hand Surgery training too.

**Mario Bonaccio,**  
**Frauenfeld and Esther Vögelin,**  
*Bern, Switzerland*

## Turkish Society of Hand and Upper Extremity Surgery

The Turkish Society of Hand and Upper Extremity Surgery was founded in 1977 by the Honorary President, Professor Rıdvan Ege. The society has 247 members, and it is a member of IFFSH and FESSH. The IFFSH meeting in 2001, and the FESSH meeting in 2013 were organised in Turkey by the society.

The society organises national hand surgery congresses every two years, and the 14th national congress will be held between May 15-18, 2014, in Bursa. These congresses are held regularly since 1992. During the last three meetings hand physiotherapists organised their own congress along with the national congress of the hand surgery society.

The society also publishes the "Hand and Microsurgery" Journal since 2012, and accepts manuscripts in both English and Turkish. Every year the society organises courses about emergency and elective hand surgery directed to the residents in hand surgery, orthopaedics and plastic surgery, as well as emergency department physicians.

The society has its own hand surgery education curriculum since 2011. Turkish Society of Hand and Upper Extremity Surgery Educational Committee is responsible for coordination of the education. The members of this committee are selected from the hand centers giving education. Hand Surgery diplomas were given by the Ministry of Health to 130 hand surgeons between 2011 and 2012, and hand surgery became a certified subspecialty in Turkey. Since 2012, there are currently in eight university and state education hospitals having hand surgery departments with residents.

[www.turkhandsociety.org](http://www.turkhandsociety.org)

# IFSSH Scientific Committee on Congenital Conditions

Chair: M Ezaki (USA). Committee: GH Baek (Korea), E Horii (Japan), S Hovius (Netherlands).

Report submitted February 2014

## Classification of Congenital Hand and Upper Limb Anomalies

Our committee recommends adoption of a revised classification system for Congenital Anomalies of the Hand and Upper Limb. The Swanson Classification was proposed in the 1960s and was subsequently adopted by the IFSSH Congenital Conditions Committee. This classification has been of significant benefit, but remains based on a morphological rather than etiological system which is unable to adapt to increasing knowledge.

Dr. Paul Manske, along with Drs. Michael Tonkin and Kerby Oberg, began working on a classification system that would incorporate newer knowledge of the etiology, molecular genetics, and developmental biology into our thinking about these conditions. After Dr. Manske's death, the work has been refined by Drs.

Tonkin and Oberg, and vetted by the members of the committee and an international study group. The current document has been discussed extensively. While no classification system is perfect, this OMT system has the ability to be flexible and respond to new developments and additional conditions. The classification of some conditions remains controversial and, for these, the principle of "best fit" has been utilized. It is designed to be a working classification that can be revised and/or modified.

It should be noted that the classification system, as proposed below, describes main groups and sub-groups, but allows for addition of surgical sub-classifications (such as those for thumb duplication, thumb hypoplasia, cleft hand, etc) within an expanded version.

The IFSSH Scientific Committee on Congenital Conditions recommends adoption of the OMT classification with reviews at 3-year intervals according to responses from the hand surgery community. The Committee invites comments and advice based on improvements in knowledge at the time of these reviews when the classification may be modified.

**"While no classification system is perfect, this OMT system has the ability to be flexible and respond to new developments and additional conditions."**

## OMT CLASSIFICATION OF CONGENITAL HAND AND UPPER LIMB ANOMALIES

### I. MALFORMATIONS

#### A. ABNORMAL AXIS FORMATION/ DIFFERENTIATION—ENTIRE UPPER LIMB

##### 1. Proximal-distal axis

- i. Brachymelia with brachydactyly
- ii. Symbrachydactyly

- a) Poland syndrome
- b) Whole limb excluding Poland syndrome
- iii. Transverse deficiency
  - a) Amelia
  - b) Clavicular/scapular
  - c) Humeral (above elbow)

- d) Forearm (below elbow)
- e) Wrist (carpals absent/at level of proximal carpals/at level of distal carpals ) (with forearm/arm involvement)
- f) Metacarpal (with forearm/arm involvement)

- g) Phalangeal (proximal/middle/distal) (with forearm/arm involvement)
- iv. Intersegmental deficiency
  - a) Proximal (humeral – rhizomelic)
  - b) Distal (forearm – mesomelic)
  - c) Total (Phocomelia)
- v. Whole limb duplication/triplication

## **2. Radial-ulnar (anterior-posterior) axis**

- i. Radial longitudinal deficiency - Thumb hypoplasia (with proximal limb involvement)
- ii. Ulnar longitudinal deficiency
- iii. Ulnar dimelia
- iv. Radioulnar synostosis
- v. Congenital dislocation of the radial head
- vi. Humero-radial synostosis - Elbow ankyloses

## **3. Dorsal-ventral axis**

- i. Ventral dimelia
  - a) Fuhmann/Al-Awadi/Raas-Rothschild syndromes
  - b) Nail Patella syndrome
- ii. Absent/hypoplastic extensor/flexor muscles

## **4. Unspecified axis**

- i. Shoulder
  - a) Undescended (Sprengel)
  - b) Abnormal shoulder muscles
  - c) Not otherwise specified
- ii. Arthrogryposis

## **B. ABNORMAL AXIS FORMATION/ DIFFERENTIATION— HAND PLATE**

### **1. Proximal-distal axis**

- i. Brachydactyly (no forearm/arm involvement)
- ii. Symbrachydactyly (no forearm/arm involvement)
- iii. Transverse deficiency (no forearm/arm involvement)
  - a) Wrist (carpals absent/at level of

proximal carpals/at level of distal carpals)

- b) Metacarpal
- c) Phalangeal (proximal/middle/distal)

## **2. Radial-ulnar (anterior-posterior) axis**

- i. Radial deficiency (thumb - no forearm/arm involvement)
- ii. Ulnar deficiency (no forearm/arm involvement)
- iii. Radial polydactyly
- iv. Triphalangeal thumb
- v. Ulnar dimelia (mirror hand – no forearm/arm involvement)
- vi. Ulnar polydactyly

## **3. Dorsal-ventral axis**

- i. Dorsal dimelia (palmar nail)
- ii. Ventral (palmar) dimelia (including hypoplastic/aplastic nail)

## **4. Unspecified axis**

- i. Soft tissue
  - a) Syndactyly
  - b) Camptodactyly
  - c) Thumb in palm deformity
  - d) Distal arthrogryposis
- ii. Skeletal deficiency
  - a) Clinodactyly
  - b) Kirner's deformity
  - c) Synostosis/symphalangism (carpal/metacarpal/phalangeal)
- iii. Complex
  - a) Complex syndactyly
  - b) Synpolydactyly— central
  - c) Cleft hand
  - d) Apert hand
  - e) Not otherwise specified

## **II. DEFORMATIONS**

- A. Constriction ring sequence
- B. Trigger digits
- C. Not otherwise specified

## **III. DYSPLASIAS**

### **A. Hypertrophy**

- 1. Whole limb
  - i. Hemihypertrophy
  - ii. Aberrant flexor/extensor/ intrinsic muscle
- 2. Partial limb
  - i. Macrodactyly
  - ii. Aberrant intrinsic muscles of hand

### **B. Tumorous conditions**

- 1. Vascular
  - i. Hemangioma
  - ii. Malformation
  - iii. Others
- 2. Neurological
  - i. Neurofibromatosis
  - ii. Others
- 3. Connective tissue
  - i. Juvenile aponeurotic fibroma
  - ii. Infantile digital fibroma
  - iii. Others
- 4. Skeletal
  - i. Osteochondromatosis
  - ii. Enchondromatosis
  - iii. Fibrous dysplasia
  - iv. Epiphyseal abnormalities
  - v. Others

## **IV. SYNDROMES\***

### **A. Specified**

- 1. Acrofacial Dysostosis 1 (Nager type)
- 2. Apert
- 3. Al-Awadi/Raas-Rothschild/Schinzel phocomelia
- 4. Baller-Gerold
- 5. Bardet-Biedl Carpenter
- 6. Catel-Manzke
- 7. Constriction band (Amniotic Band Sequence)
- 8. Cornelia de Lange (types 1-5)
- 9. Crouzon
- 10. Down
- 11. Ectrodactyly-Ectodermal Dysplasia-Clefting

12. Fanconi Pancytopenia  
13. Fuhrmann  
14. Goltz  
15. Gorlin  
16. Greig Cephalopolysyndactyly  
17. Hajdu-Cheney  
18. Hemifacial Microsomia (Goldenhar syndrome)  
19. Holt-Oram  
20. Lacrimoauriculodentodigital (Levy-Hollister)  
21. Larsen  
22. Leri-Weill Dyschondrosteosis  
23. Moebius sequence

24. Multiple Synostoses  
25. Nail-Patella  
26. Noonan  
27. Oculodentodigital dysplasia  
28. Orofacialdigital  
29. Otopalataldigital  
30. Pallister-Hall  
31. Pfeiffer  
32. Poland  
33. Proteus  
34. Roberts-SC Phocomelia  
35. Rothmund-Thomson  
36. Rubinstein-Taybi  
37. Saethre-Chotzen

38. Thrombocytopenia Absent Radius  
39. Townes-Brock  
40. Trichorhinophalangeal (types 1-3)  
41. Ulnar-Mammary  
42. VACTERLS association

## B. Others

\*The specified syndromes are those considered most relevant; however, many other syndromes have a limb component categorized under "B. Others".

*OMT Classification 3rd February, 2014*

# IFSSH Scientific Committee on Genetics in Hand Surgery

Chair: Kerby C. Oberg (USA).

Committee: Maria A. Ros (Spain), Charles A. Goldfarb (USA)

Report submitted May 2013

## New Insights on Upper Limb Development: Digitising the Hand

During the 5th week of human development, the distal end of the upper limb bud begins to flatten and expand forming the autopod or handplate. Over the next few days the handplate will transform into a predictable series of segmented digits. The molecular mechanisms underlying digit formation are not fully understood, however, recent investigations in animal models

and clinical genetics provide some interesting insights into the process.

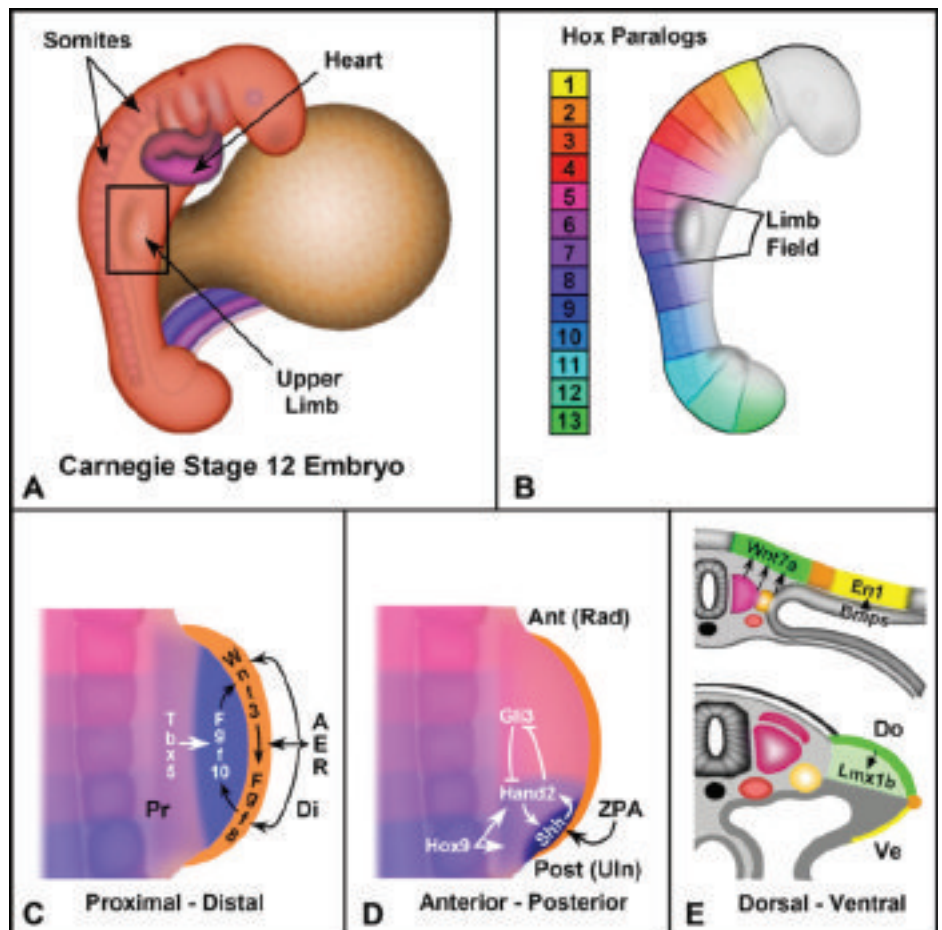
### Limb initialisation, outgrowth and developmental axes

The position of the upper limb along the cranial-caudal axis is established by Hox transcription factors (Fig. 1a and 1b)<sup>3,42</sup>. Within the presumptive upper limb field, Hox transcription factors up-regulate the T-box containing

transcription factor 5 (TBX5) which, in turn, up-regulates fibroblast growth factor 10 (FGF10) secretion to promote upper limb bud initiation and outgrowth<sup>1,15,20,24,31</sup>. The subsequent morphogenesis of the emerging limb bud can be described in terms of three coordinate axes – the proximal-distal axis, the anterior-posterior (or radial-ulnar) axis and the dorsal-ventral (or dorsal-volar) axis as depicted in Figure



**Figure 1. Limb Induction and Signaling Center Formation.** A) Depiction of an emerging upper limb bud in Carnegie stage 12 embryo. B) *Hox* genes establish upper limb position and polarity. C) Cascade of events that initiate limb bud formation and proximal distal polarity with formation of the apical ectodermal ridge (AER) and induction of *Fgf8*. D) Cascade of events that induce the expression of *Shh* and formation of the zone of polarising activity establishing radial-ulnar (anterior-posterior) polarity. E) Unknown factors in somites and/or intermediate mesoderm initiate *Wnt7a* expression in what will become the dorsal ectoderm. *Bmps* induce the expression of *En1* in what will become the ventral ectoderm and thereby establishes the dorsal ventral boundary where the AER will form (orange).



1. Each of these axes is controlled by a signaling center that initiates a cascade of axis-related pathways. Although all three axis-related pathways contribute to digit formation, the anterior-posterior axis establishes the number of digits and digit-specific morphology (phalange size and number) and will be the primary focus of this report.

Prior to handplate formation, expression of the first phase of distal HOXD transcription factors (HOXD10-13) occurs in a nested collinear fashion along the anterior-posterior axis, with HOXD10 exhibiting the largest initial expression domain. Each successively more distal HOXD transcription factor is nested within the previous gene's expression domain (See Figure 2). HOXD13, the terminal transcription

factor in the HOXD cluster, has the smallest expression domain and overlaps the zone of polarising activity (ZPA), within the distal posterior or ulnar aspect of the limb bud. This first phase of distal HOXD expression corresponds to the forearm or zeugopod specification.

Sonic hedgehog (SHH) is secreted from the ZPA and establishes a posterior to anterior gradient along the anterior-posterior (radial-ulnar) axis. SHH manifests its action via the family of GLI-Krupple zinc finger transcription factors (GLI1, GLI2 and GLI3). Of these GLI3 is the most important during limb development. In the absence of SHH, Gli3 is processed into a truncated form that is a strong transcriptional repressor (GLI3R)<sup>27,38</sup>. SHH inhibits

this processing, thus the posterior-anterior SHH gradient is translated into a complementary anterior-posterior intracellular gradient of GLI3R (See Figure 2)<sup>38</sup>. SHH/GLI3 regulation is critical for posterior (ulnar) limb proliferation and distal patterning (forearm and hand)<sup>33,44</sup>.

### Digitising the handplate

The handplate is the last segment of the limb bud to form, appearing about 37 days post ovulation (Carnegie stage 16, Figure 2). As the handplate forms, several molecular pathways converge. HOXA13, the terminal Hox transcription factor of the HOXA cluster, is induced in the distal limb bud demarcating the handplate boundary<sup>41,43</sup>. Concurrently, a second

“late”, SHH-regulated phase of distal HOXD expression (that corresponds with digit formation) is generated that partially reverses their expression domains, i.e., reversed colinearity<sup>19</sup>. In addition, there is a graded expression intensity with HOXD13 exhibiting the most robust expression within the

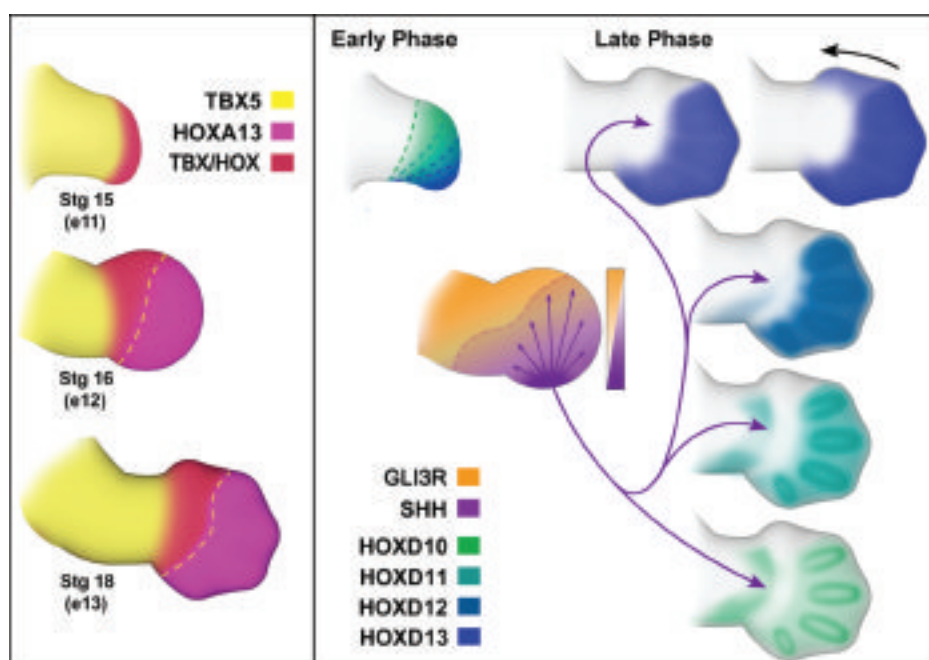
digits, and HOXD10 exhibiting the least intense expression, what has been termed quantitative colinearity<sup>11</sup>.

Experimental evidence suggested that the ZPA produced a diffusible morphogen that established a spatial concentration gradient across the anterior-posterior limb bud axis<sup>29</sup>.

This provided cells with a positional value according to their position within the gradient field. SHH was subsequently identified and validated as the morphogen secreted by the ZPA critical for limb patterning and digit identity<sup>9,23</sup>. More recently, SHH has been shown to have dual, separable functions in both patterning and growth<sup>33,44</sup>.

The accumulated evidence suggests that these molecules work collectively to establish the five digit pattern common to most tetrapods (animals with four limbs). Although a molecular gradient has been a popular hypothesis, a gradient model does not fully explain the repeating digital-interdigital pattern. Recent analysis of compound deletions of distal Hox (Hoxa13, Hoxd11-13) and Gli3 genes in mice, exposed an intrinsic self-organising mechanism involved in patterning the digits<sup>28</sup>. With the progressive reduction of HOX gene dose in the absence of Gli3, there is a progressive increase in digit numbers (up to 14 digits) that is not accompanied by a corresponding increase in handplate size, thus the digits are increasingly thinner and shorter.

Alan Turing first proposed a mathematical diffusion-reaction model to account for repetitive self-organising patterns, such as stripes or spots in animal skin and fur<sup>34</sup>. This model proposes two molecules, an activator and inhibitor, which diffuse into a field of cells. The activator auto-upregulates itself and upregulates its own inhibitor. In contrast, the model's inhibitor suppresses the activator and auto-inhibits its own expression (see Figure 3).

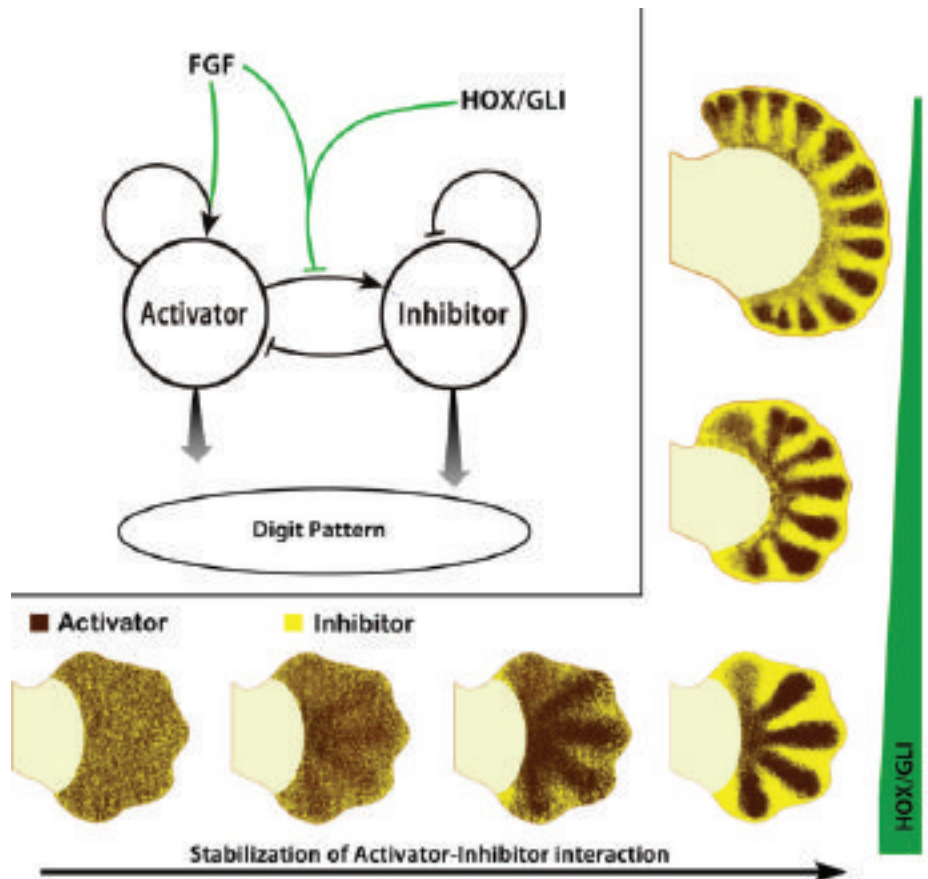


**Figure 2. Molecular Pathways Regulating Digit Formation.** *TBX5* expression (yellow) persists as the autopod forms (Carnegie stage 16, post fertilisation day 37; comparable to mouse embryonic day 12 or e12) and begins to differentiate (Carnegie stage 18, post fertilisation day 44; comparable to mouse e13). However, expression of *TBX5* in the autopod is limited to the anterior-proximal aspect (illustrated as a yellow-dashed line). *HOXA13* is expressed within autopod cells (illustrated as magenta) and delineates the proximal autopod boundary. Interestingly, digit 1 or the thumb, is the only digit to have the combined expression both *TBX5* and *HOXA13*. The distal *HOXD* complex (*HOXD10-13*) is expressed in a nested collinear pattern in early limb development (early phase, Stg 15 or mouse e11). This nested pattern is also thought to participate in the induction or maintenance of *SHH* expression. *GLI3* processing by *SHH* (purple) sets up an anterior-posterior gradient of *GLI3* repressor (*GLI3R*) (orange). *SHH* also regulates the expression of the distal *HOXD* transcription factors (*HOXD10-13*) (Carnegie Stg 18 or mouse e13) within increasing intensity (quantitative colinearity). These transcription factors appear to physically interact with *GLI3* to refine digit identity (the *SHH* dependent boundary is highlighted by a purple dashed line). *HOXD 10-12* have overlapping expression domains in presumptive digits 2-5, but are restricted from the thumb domain. *HOXD13* in contrast is expressed in all of the digit domains including the presumptive thumb, though its late extension into the thumb domain is *SHH* independent.

Small random molecular fluctuations of the activator and the inhibitor eventually lead to steady patterns, usually spots or stripes. The pattern is dependent upon the robustness of activator and inhibitor expression as well as their diffusion rates. This intrinsic self-organising or Turing mechanism controls the initial alternating digit/non digit pattern in the handplate. Although the molecular identity of the activator and inhibitor are not yet known, these investigations indicate that the terminal HOXA/D transcription factors, in concert with SHH/Gli3 regulation, modulate the intrinsic self-organising mechanism and are critical in resolving the common digit-interdigit pattern of pentadactyly.

Once the number of digits has been established, digit specific morphologies are determined. The mechanisms that regulate digit morphology are not fully characterised, but at the distal end of each digit there is a thin cap of cells called the phalanx forming region (PFR) or digital crescent (Figure 4)<sup>16,30</sup>. Signals from the adjacent posterior interdigital tissue regulate digit morphology and function relatively late as the phalanges are progressively being formed<sup>6</sup>. Our current understanding suggests that SHH – Gli3R/Gli3FL counter gradients and SHH-regulated HOXD10-13 transcription factors (particularly for digits 2-5), likely through BMPs (predominantly BMP2, 4 & 7) and from AER-related FGFs and WNTs instruct the PFR to form the appropriate number and size of phalanges<sup>16,25,26,30,39,40</sup>.

The thumb domain is somewhat



**Figure 3. Turing-Like Patterning in Limbs.** In the upper left-hand boxed region is a diagram of the diffusion-driven instability model with an activator and inhibitor. Modulation of this intrinsic self-organising mechanism (ISOM) by FGF and HOX/GLI is also depicted. In the model described by Sheth et al. (2012), FGF from the apical ectodermal ridge (AER) promotes a radial stripe pattern from the ISOM and ultimately regulates digit length (blue), while FGF in concert with distal HOX and GLI transcription factors limit the number of digits (green). On the bottom of the figure, a series of handplates show the rapid progression from fluctuating activator-inhibitor interaction (noise) to a stabilised 5-digit pattern. On the right, progressive loss of digit suppressing HOX/GLI transcription factors (green bar) causes an increase in the number of digits patterned by the ISOM.

different, expressing factors that are thought to influence the specialised morphology of the thumb<sup>21</sup>. TBX5 expression extends into the proximal handplate, associated with the presumptive carpals and thumb, but does not extend into the ulnar digits (digits 2-5)(Figure 2)<sup>12</sup>. Moreover, the thumb domain is accentuated by

the lack of HOXD10-12 expression and only the most terminal HOX transcription factors, i.e., HOXA13 and HOXD13, are expressed.

When the digit morphology has been established, the AER regresses and the terminal phalanges begin to form<sup>5,26</sup>. Formation of terminal phalanges is morphologically and



mechanistically different from other phalanges. Although a cartilage model forms similar to other phalanges, ossification begins at the distal tapered tip rather than as a collar around the mid-shaft<sup>4</sup>. A keratinised nail also forms on the dorsal aspect of the terminal or ungual phalanx. In mice, the terminal phalanges are demarcated molecularly by the expression of Bambi, a Bmp inhibitor, and Sp8, a member of the specificity protein family of transcription factors that mediates Wnt signaling (Figure 4, last panel)<sup>4,10</sup>. In addition, the terminal phalanx retains the expression of MSX1, a transcription factor that is thought to convey the capacity for fingertip regeneration<sup>2,7</sup>.

## Clinical Genetics

While animal models are important in characterising many of the pathways that regulate digit formation, genetic analysis of patients with congenital upper limb anomalies are instrumental in providing relevant molecules to investigate and in confirming

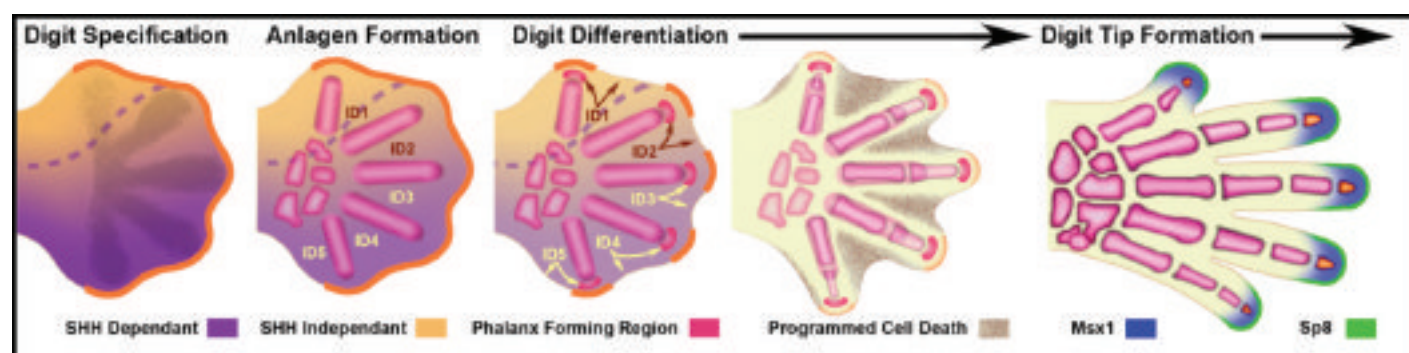
**“The molecular mechanisms underlying digit formation are not fully understood, however, recent investigations in animal models and clinical genetics provide some interesting insights into the process.”**

conservation of suspected pathways. For example, disruption of GLI3 was first recognised in patients with Greig cephalopolysyndactyly<sup>37</sup>. GLI3 was subsequently confirmed as the molecule disrupted in the mouse mutant extra-toes (Xt), that had some features akin to Greig cephalopolysyndactyly<sup>36</sup>. However, it was several years later before GLI3

was recognised as the transcription factor mediating SHH function<sup>14</sup>. Limb features in patients with this autosomal dominant mutation include broad thumbs with a central phalangeal defect/hole and distal phalangeal duplication, features similar to those seen in heterozygote mouse knockouts indicating functional conservation of GLI3 in vertebrate limb patterning<sup>32</sup>{personal observation, Ros MA).

Similarly, functional conservation of SHH in limb patterning and its limb specific regulation have also been demonstrated in humans. In fact, it was point mutations in patients with preaxial polydactyly type II or triphalangeal thumbs that unveiled the vertebrate ZPA regulatory sequence (ZRS){Lettice, 2002 1362 /id;Lettice, 2003 1360 /id}.

Based on animal models, loss of SHH function would limit ulnar expansion and affect the development of the ulna and ulnar digits, features known clinically as ulnar longitudinal



**Figure 4. Digit Morphogenesis.** After establishing digit number and the SHH dependent/independent domains, digit morphologies are specified. Digit morphologies are determined by the adjacent posterior interdigital mesoderm as illustrated (ID1–ID5). The interdigital tissue conveys specified digit morphology to the phalanx forming region (PFR—magenta) capping the distal tip of each digital anlagen. The PFR, in concert with the AER (orange), determines phalanx size, length and positioning of joints. The interdigital tissue subsequently undergoes Bmp mediated programmed cell death (speckled regions). As the AER regresses the distal or ungual phalanx begins to form and is demarcated by expression of mesodermal Msx1 (blue) and ectodermal Sp8 (green). (Image adapted from Oberg et al., 2010)



deficiency. However, in humans, no syndromic or genetic basis of ulnar longitudinal deficiency has yet been identified.

Disruptions of distal HOXD and HOXA genes also have known mutations that demonstrate their involvement in hand development. Synpolydactyly has been linked to HOXD13 mutation and has central polydactyly supporting a role for HOXD13 in defining the number of digits formed<sup>18</sup>. While Hand-foot-uterus syndrome is caused by disruption in HOXA13 and is characterised by shortened thumbs and little fingers, occasionally with hypoplastic middle phalanges reducing the digital lengths of all of the fingers<sup>17,35</sup>. These findings support a role for HOXA13 in establishing digital lengths.

The thumb is an unusual digit and from a developmental biology standpoint, is differentiated from other digits by being the last to form, being independent of SHH, and lacking the expression of the distal HOXD genes. These features also appear to put the thumb at significant risk of disruption as over 1100 syndromes have hypoplastic thumbs as a feature<sup>21</sup>. Thus, it appears that thumb development (radial longitudinal deficiency) is most frequently impaired following any disruption that compromises the width of the handplate, particularly with persistent SHH function preserving the posterior or ulnar aspect of the limb bud<sup>13,22</sup>.

Molecular contributions to the terminal phalanx proposed by animal models have also been demonstrated in humans<sup>2</sup> and implicated in the

conserved regenerative capacity of digit tips<sup>8</sup>. These past recent successes in delineating the molecular basis of hand development encourage continued genetic evaluation of limb malformations to further characterise the involved pathways. Further discoveries are likely to occur from this synergistic relationship between clinical genetics and developmental biology.

## References

- Agarwal P, Wylie JN, Galceran J et al. Tbx5 is essential for forelimb bud initiation following patterning of the limb field in the mouse embryo. *Development* 2003;130:623-633.
- Allan CH, Fleckman P, Fernandes RJ et al. Tissue response and Msx1 expression after human fetal digit tip amputation in vitro. *Wound Repair Regen* 2006;14:398-404.
- Burke AC, Nelson CE, Morgan BA, Tabin C. Hox genes and the evolution of vertebrate axial morphology. *Development* 1995;121:333-346.
- Casanova JC, Badia-Careaga C, Uribe V, Sanz-Ezquerro JJ. Bambi and Sp8 expression mark digit tips and their absence shows that chick wing digits 2 and 3 are truncated. *PLoS One* 2012;7:e52781.
- Casanova JC, Sanz-Ezquerro JJ. Digit morphogenesis: is the tip different? *Dev Growth Differ* 2007;49:479-491.
- Dahn RD, Fallon JF. Interdigital regulation of digit identity and homeotic transformation by modulated BMP signaling. *Science* 2000;289:438-441.
- Han M, Yang X, Farrington JE, Muneoka K. Digit regeneration is regulated by Msx1 and BMP4 in fetal mice. *Development* 2003;130:5123-5132.
- Han M, Yang X, Lee J, Allan CH, Muneoka K. Development and regeneration of the neonatal digit tip in mice. *Dev Biol* 2008;315:125-135.
- Harfe BD, Scherz PJ, Nissim S, Tian H, McMahon AP, Tabin CJ. Evidence for an expansion-based temporal Shh gradient in specifying vertebrate digit identities. *Cell* 2004;118:517-528.
- Kawakami Y, Esteban CR, Matsui T, Rodriguez-Leon J, Kato S, Izpisua Belmonte JC. Sp8 and Sp9, two closely related buttonhead-like transcription factors, regulate Fgf8 expression and limb outgrowth in vertebrate embryos. *Development* 2004;131:4763-4774.
- Kmita M, Fraudeau N, Herault Y, Duboule D. Serial deletions and duplications suggest a mechanism for the collinearity of Hoxd genes in limbs. *Nature* 2002;420:145-150.
- Koshiba-Takeuchi K, Takeuchi JK, Arruda EP et al. Cooperative and antagonistic interactions between Sall4 and Tbx5 pattern the mouse limb and heart. *Nat Genet* 2006;38:175-183.
- Lee J, Tickle C. Retinoic acid and pattern formation in the developing chick wing: SEM and quantitative studies of early effects on the apical ectodermal ridge and bud outgrowth. *J Embryol Exp Morphol* 1985;90:139-69:139-169.
- Marigo V, Johnson RL, Vortkamp A, Tabin CJ. Sonic hedgehog differentially regulates expression of GLI and GLI3 during limb development. *Dev Biol* 1996;180:273-283.
- Minguillon C, Nishimoto S, Wood S, Vendrell E, Gibson-Brown JJ, Logan MP. Hox genes regulate the onset of Tbx5 expression in the forelimb. *Development* 2012;139:3180-3188.
- Montero JA, Lorda-Diez CI, Ganan Y, Macias D, Hurler JM. Activin/TGFbeta and BMP crosstalk determines digit chondrogenesis. *Dev Biol* 2008;321:343-356.
- Mortlock DP, Innis JW. Mutation of HOXA13 in hand-foot-genital syndrome. *Nat Genet* 1997;15:179-180.
- Muragaki Y, Mundlos S, Upton J, Olsen BR. Altered growth and branching patterns in synpolydactyly caused by mutations in HOXD13. *Science* 1996;272:548-551.

- 19 Nelson CE, Morgan BA, Burke AC et al. Analysis of Hox gene expression in the chick limb bud. *Development* 1996;122:1449-1466.
- 20 Ng JK, Kawakami Y, Buscher D et al. The limb identity gene Tbx5 promotes limb initiation by interacting with Wnt2b and Fgf10. *Development* 2002;129:5161-5170.
- 21 Oberg KC. Review of the Molecular Development of the Thumb: Digit Primera. *Clin Orthop Relat Res* 2013.
- 22 Raynaud A, Clergue-Gazeau M. [Chemically induced ectropodia in the *Lacerta viridis* embryo and formation of styliform limbs in reptiles]. *C R Acad Sci III* 1984;298:457-460.
- 23 Riddle RD, Johnson RL, Laufer E, Tabin C. Sonic hedgehog mediates the polarizing activity of the ZPA. *Cell* 1993;75:1401-1416.
- 24 Rodriguez-Esteban C, Tsukui T, Yonei S, Magallon J, Tamura K, Izpisua Belmonte JC. The T-box genes Tbx4 and Tbx5 regulate limb outgrowth and identity. *Nature* 1999;398:814-818.
- 25 Rowe DA, Cairns JM, Fallon JF. Spatial and temporal patterns of cell death in limb bud mesoderm after apical ectodermal ridge removal. *Dev Biol* 1982;93:83-91.
- 26 Sanz-Ezquerro JJ, Tickle C. Fgf signaling controls the number of phalanges and tip formation in developing digits. *Curr Biol* 2003;13:1830-1836.
- 27 Schweitzer R, Vogan KJ, Tabin CJ. Similar expression and regulation of Gli2 and Gli3 in the chick limb bud. *Mech Dev* 2000;98:171-174.
- 28 Sheth R, Marcon L, Bastida MF et al. Hox genes regulate digit patterning by controlling the wavelength of a Turing-type mechanism. *Science* 2012;338:1476-1480.
- 29 Summerbell D. The control of growth and the development of pattern across the anteroposterior axis of the chick limb bud. *J Embryol Exp Morphol* 1981;63:161-80;161-180.
- 30 Suzuki T, Hasso SM, Fallon JF. Unique SMAD1/5/8 activity at the phalanx-forming region determines digit identity. *Proc Natl Acad Sci U S A* 2008;105:4185-4190.
- 31 Takeuchi JK, Koshiba-Takeuchi K, Suzuki T, Kamimura M, Ogura K, Ogura T. Tbx5 and Tbx4 trigger limb initiation through activation of the Wnt/Fgf signaling cascade. *Development* 2003;130:2729-2739.
- 32 te Welscher P, Zuniga A, Kuijper S et al. Progression of vertebrate limb development through SHH-mediated counteraction of GLI3. *Science* 2002;298:827-830.
- 33 Towers M, Mahood R, Yin Y, Tickle C. Integration of growth and specification in chick wing digit-patterning. *Nature* 2008;452:882-886.
- 34 Turing AM. The chemical basis of morphogenesis. 1953. *Bull Math Biol* 1990;52:153-197.
- 35 Verp MS, Simpson JL, Elias S, Carson SA, Sarto GE, Feingold M. Heritable aspects of uterine anomalies. I. Three familial aggregates with Mullerian fusion anomalies. *Fertil Steril* 1983;40:80-85.
- 36 Vortkamp A, Franz T, Gessler M, Grzeschik KH. Deletion of GLI3 supports the homology of the human Greig cephalopolysyndactyly syndrome (GCPS) and the mouse mutant extra toes (Xt). *Mamm Genome* 1992;3:461-463.
- 37 Vortkamp A, Gessler M, Grzeschik KH. GLI3 zinc-finger gene interrupted by translocations in Greig syndrome families. *Nature* 1991;352:539-540.
- 38 Wang B, Fallon JF, Beachy PA. Hedgehog-regulated processing of Gli3 produces an anterior/posterior repressor gradient in the developing vertebrate limb. *Cell* 2000;100:423-434.
- 39 Winkel A, Stricker S, Tylzanowski P et al. Wnt-ligand-dependent interaction of TAK1 (TGF-beta-activated kinase-1) with the receptor tyrosine kinase Ror2 modulates canonical Wnt-signalling. *Cell Signal* 2008;20:2134-2144.
- 40 Witte F, Chan D, Economides AN, Mundlos S, Stricker S. Receptor tyrosine kinase-like orphan receptor 2 (ROR2) and Indian hedgehog regulate digit outgrowth mediated by the phalanx-forming region. *Proc Natl Acad Sci U S A* 2010;107:14211-14216.
- 41 Woltering JM, Duboule D. The origin of digits: expression patterns versus regulatory mechanisms. *Dev Cell* 2010;18:526-532.
- 42 Xu B, Wellik DM. Axial Hox9 activity establishes the posterior field in the developing forelimb. *Proc Natl Acad Sci U S A* 2011;108:4888-4891.
- 43 Yokouchi Y, Sasaki H, Kuroiwa A. Homeobox gene expression correlated with the bifurcation process of limb cartilage development. *Nature* 1991;353:443-445.
- 44 Zhu J, Nakamura E, Nguyen MT, Bao X, Akiyama H, Mackem S. Uncoupling Sonic hedgehog control of pattern and expansion of the developing limb bud. *Dev Cell* 2008;14:624-632.

\*A general summary of upper limb development can be reviewed at: <http://digitalav.llu.edu/llu/sm/oberg/assh/index.htm> (Courtesy of the American Society for Surgery of the Hand)

# IFSSH Scientific Committee on Anatomy and Biomechanics

Chair: Hisao Moritomo (Japan)

Committee: Emmanuel P. Apergis (Greece), Marc Garcia-Elias (Spain), Frederick Werner (USA), Scott Wolfe (USA)

Report submitted September 2013

## Wrist biomechanics and Instability: Wrist dart-throwing motion updated

### Introduction

The term “dart-throwing” (DT) motion, or dart-thrower’s motion, is used to designate one of the most frequently utilised planes of wrist motion, the one that brings the wrist from a radially deviated-extended position (radial extension) to an ulnarly deviated-flexed position (ulnar flexion).<sup>1</sup> DT motion is particularly prevalent in most occupational, recreational and avocational activities, such as hammering, clubbing or fly fishing.<sup>2-6</sup> In 2007, the IFSSH (International Federation of Societies for Surgery of the Hand) Committee on Wrist Biomechanics published a historical perspective and a summary of the basic principles of DT biomechanics.<sup>1</sup> The purpose of this article is to update that report based on the most recent research published on the kinematics, kinetics, and clinical applications of DT motion.

### Carpal kinematics

The wrist is a composite joint. When it moves, a complex interaction and accumulation of motions occur at its different levels. For the wrist to reach its maximal range, all of its joints [radiocarpal (RC), midcarpal (MC) and

intercarpal] must collaborate in that rotation. That rule has two exceptions: 1) when the wrist rotates along the DT plane of motion, only the MC joint moves about a proximal row that remains still, and 2) when the wrist rotates along the so-called reversed DT plane of motion (from ulnar extension to radial flexion), motion occurs almost exclusively at the RC joint. From a kinematic point of view, therefore, the wrist can be compared to a universal joint with two axes of motion, one for the RC joint, another for the MC joint, separated by an intercalated segment (the proximal row) aimed at coordinating the two levels of rotation. What follows is a review of the studies that have provided new data in these regards.

Crisco et al.<sup>7</sup> predicted near-zero scaphoid rotation when the wrist rotates along an oblique plane oriented at an angle of 33° to the sagittal plane, while for the lunate to remain still, the wrist needs to move along an oblique plane 20° to the sagittal plane. These values are slightly inferior to the ones reported by Werner et al. who found that, to obtain minimal scaphoid and lunate rotations, the wrist needs to move along motion

paths oriented at an angle of 45° and 37° respectively to the sagittal plane.<sup>8</sup> It is important to note, that in both investigations the wrist was mobilised taking the neutral wrist position as a reference (zero degrees on both flexion-extension and radio-ulnar deviation). Indeed, one may bring the hand from radial extension to neutral and continue from neutral to ulnar flexion, following an oblique plane that intercepts both the coronal and sagittal planes at the same time. This, however, is not the most common. More often on actual activities, DT rotation is done along an oblique plane that is parallel to the previous one, but that has an offset toward the dorsal side and does not intercept the coronal and sagittal planes at the zero position<sup>5,9</sup>. When this happens, that DT plane is said to be a “functional” DT plane. By contrast, when the wrist takes an oblique path across the neutral wrist position, the DT plane is said to be a “pure” DT plane. The kinematic differences of mobilising the wrist along a “pure” or a “functional” DT planes are not fully understood, but certainly the subject deserves specific attention. There are circumstances

in which it may be advisable to rehabilitate a wrist by performing repeated rotations along a pure DT plane of motion; in other cases it may be advisable to avoid such commonly used paths. In general, it is admitted that, after certain types of radiocarpal and/or proximal row reconstructions, motion along a pure DT plane can be allowed without concern for disruption or attenuation of the reconstruction, because the proximal row remains relatively still during that particular type of rotation.<sup>10</sup>

There are still many unknowns in regards the kinematics of DT motion. For instance, it is still unclear whether the functional DT plane of motion which is used most commonly in activities of daily living (such as in hammering) is the same as the pure DT plane where scaphoid and lunate motion is minimal. The recent findings regarding the relative contribution of the radiocarpal joint to the overall wrist motion during DT rotation have vary substantially from one author to another<sup>7,8,11-13</sup>. Scaphoid rotation during DT motion has been reported to be as little as 26% and as much as 50% of overall wrist motion, while the range of reported lunate rotations has varied from 22% to 40% of overall wrist motion. While it is convenient to imagine a single plane of motion that enables complex wrist functions, most researchers agree that several DT motion paths of composite radio-ulnar and flexion-extension are likely to contribute to a wide variety of functional activities.

Leventhal et al.<sup>14</sup> examined healthy volunteers with computed tomography (CT) scans, performing

a simulated hammering task, using a path of wrist motion from radial extension to ulnar flexion, and found that during a simulated hammering task the rotations of the scaphoid and lunate were not minimal but averaged 40% and 41% respectively of total wrist motion. According to that, radiocarpal motion accounted for 40% of the overall wrist motion, with the remaining 60% occurring at the midcarpal joint. These greater percentages of scaphoid and lunate motion during hammering, as compared to the ones found for pure DT motion with near zero scaphoid and lunate motion, appear to indicate that, indeed, pure DT and functional DT are different wrist motion paths. Furthermore, in that study, the average plane of motion while hammering was oriented 41° from the sagittal plane, and was parallel to the pure DT plane with a substantial offset between the two. From that study we learned that, motions which require a greater range of gripping force, such as hammering, are likely to exhibit greater ranges of scaphoid and lunate motion. In other words, there exist a wide range of DT planes, parallel to the “pure” DT plane, each with its own advantages when it comes to move while grasping or gripping an object.

Crisco et al.<sup>15</sup> demonstrated in the cadaver that mechanical axis of the wrist, and found this not to be aligned with the anatomical sagittal or coronal axes of the hand. The envelope of all possible wrist positions was ellipsoidal in shape and oriented obliquely at a mean angle of  $26.6^\circ \pm 4.4^\circ$  to the sagittal plane of motion.<sup>15</sup> It was also noted that the greatest total range

of motion, in the direction of radial extension to ulnar flexion, was 142° which was greater than their total range of flexion-extension motion of 129°. This supports the concept that a functional DT facilitates those activities which require greater wrist motion.

Because several DT paths of composite radio-ulnar and flexion-extension are likely to contribute in a variety of functional activities, the term “coupled” wrist motion is emerging as a more inclusive term for describing out-of-plane motion from a kinematic, clinical and rehabilitative perspective<sup>16</sup>. Measuring coupled wrist motion clinically has presented unique challenges. While goniometric measurement of the conventional orthogonal planes of flexion-extension and radio-ulnar deviation has been demonstrated to be accurate and repeatable within 10 degrees,<sup>17</sup> no similar reliability study has been performed for manual measurement of coupled motions or postures. The technique and challenges of measuring coupled motion along the DT plane in a rehabilitation practice were recently outlined by Bugden<sup>18</sup>.

The emergence of in vivo three-dimensional motion analysis techniques [markerless bone registration technique using sequential CT or magnetic resonance imaging (MRI)] enabled precise analysis of complex motions of the individual carpal bones in live subjects<sup>7,10,13,14,19-22</sup>. However, we need to be careful in interpreting these results because the technique is limited to a quasi-static analysis of wrist motion and the inability to recreate physiologic rheology conditions of the joint in the



3-dimensional gantry. Additionally, the levels of ionizing radiation limit the use of this technique in general practice. The use of so-called 4-dimensional advanced imaging, whether fluoroscopy, ultra-fast CT scans or MRI, is evolving<sup>23-25</sup> and has already been found useful to study what happens within the carpus when a wrist with a scapholunate dissociation rotates along a DT plane.<sup>25</sup> Garcia-Elias et al reported that, when the scapholunate ligaments were torn, the scaphoid shifted towards the radial styloid considerably more than the lunate, inducing a scapholunate gap.<sup>25</sup> Based on these findings, they did not recommend dart-throwing exercises after scapholunate ligament repair.<sup>25</sup> Video recording of motion can qualitatively demonstrate differences in circumduction arcs between normal and injured wrists or between patients, but cannot yet be utilized currently to provide objective kinematic data.

Recently, unique algorithms for kinematic analysis using applied skin optimal marker sets and measured by multiple simultaneous video cameras have been effectively utilized to accurately quantify normal motion during functional activities.<sup>9,26,27</sup> It is likely that these techniques will further evolve to facilitate accurate upper extremity analysis and reporting in vivo. Brigstock et al<sup>9</sup> using passive reflective markers and 3-dimensional motion analysis in 10 subjects, confirmed in vivo the use of DT motion during daily activities in both seated (forehand hair combing, backhand hair combing and drinking from a glass) and standing positions (hammering a nail, throwing a ball, pouring from a jug, undoing

## **"It is also a common belief that early mobilisation and prompt physiotherapy prevent the development of CRPS after fractures."**

a button, doing-up a button, and twisting off and on the lid of a jar). They found the mean plane of a measured simulated DT motion to be 44° to the sagittal plane of the forearm, inclined from a position of radial extension to ulnar flexion. They demonstrated that wrist motion approximated the DT motion when hammering a nail, throwing a ball, drinking from a glass, pouring from a jug and twisting off and on the lid of a jar since their planes of motion ranged from 38 to 48 degrees from the sagittal plane and were not significantly different from the simulated dart throw motion plane. Two activities were found to not have a plane of motion similar to a dart throw motion; combing hair or buttoning or undoing a button.

### **Impact of carpal bone fusions on DT motion**

Disorders that affect DT motion include anything that disrupts the coordinated gliding of the radiocarpal or midcarpal joints, including ligament disruption, post-traumatic or degenerative arthritis, inflammatory arthritis, Kienböck's disease, or Preiser's disease. Garg et al<sup>28</sup> examined the relationship

between wrist coupling (the amount of flexion-extension per degree of radial-ulnar deviation) and functional performance in patients after midcarpal arthrodesis. They found that altered wrist coupling will result in diminished performance in selected occupational and sporting activities (dart throwing, hammering, pouring, and basketball tasks). Compensations afforded by the elbow and shoulder may influence the performance of certain functional tasks.

Several authors have recently recommended radiocarpal rather than midcarpal fusions (if the cartilage in the midcarpal joint is intact), in order to preserve midcarpal function. Arimitsu et al reported that the midcarpal motions were well preserved after both radio-lunate and radio-scapho-lunate arthrodesis<sup>20</sup>. The postoperative direction of wrist motion in their study was oblique from radiodorsal to ulnopalmar along a DT plane. Additionally, it has been demonstrated that midcarpal and lunotriquetral motion are increased after simulated radio-scapho-lunate fusion<sup>29,30</sup>. Moritomo et al revealed that capitate motion relative to the scaphoid was essentially uniaxial and that the motion plane was oblique from radiodorsal to ulnopalmar, whereas the direction of capitate motion relative to the lunate had more flexibility and could range between the pure flexion-extension plane and the DT plane<sup>13</sup>. Therefore, the residual motion plane of the capitate after radio-lunate arthrodesis is more flexible than after radio-scapho-lunate arthrodesis.<sup>20</sup> If the scaphoid is fixed to the lunate, the direction of capitate motion relative to the lunate is

dominated by the direction of capitate motion relative to the scaphoid and limited to the DT plane.

Distal scaphoidectomy has been developed in order to improve the range of motion after radio-scapholunate arthrodesis.<sup>31</sup> There are reports that distal scaphoidectomy also improves fusion rates and lowers the incidence of midcarpal arthritis<sup>31</sup>. However, distal scaphoidectomy could alter the kinematic behavior of the remaining joints with unknown consequences. Since it was suggested that the scaphotrapezium-trapezoid joint is a key anatomical factor that stabilises and controls DT motion<sup>32</sup>, distal scaphoidectomy could abolish the plane of DT motion and how the wrist moves through an oblique DT motion -like plane of motion. We need long-term surgical outcomes to better elucidate these concerns.

Kamal et al<sup>22</sup> measured the in vivo articulation of the triquetrum-hamate joint as the wrist moves along the DT path. The study suggested that wrist ulnar flexion is constrained by the triquetrum-hamate joint. The concave distal ridge of the hamate guides the triquetrum toward the hook of the hamate until it is fully engaged, which blocks further ulnar flexion of the wrist. This may provide carpal stability while also serving as a rationale for triquetrum excision to increase the range of wrist motion. Pervais<sup>33</sup> postulated that removal of both the triquetrum and distal scaphoid converts the complex midcarpal joint into a simple ball and socket joint, though the kinematics of that condition have not been fully studied. It is possible that the benefit from an

increase in midcarpal motion may be offset by the well-established belief that altered kinematics may change load distribution and accelerate degenerative osteoarthritis<sup>34</sup>.

## Coupling of wrist and forearm rotations

Anderton and Charles<sup>35</sup> tried to quantify the coordination and coupling of wrist and forearm rotations in healthy subjects performing activities of daily living. They reported that flexion of the wrist is often accompanied by ulnar deviation and supination, and extension is often accompanied by radial deviation and pronation. On the contrary, Leventhal et al<sup>14</sup> stated that hammering is performed with limited forearm pronation/supination motion. More study will be needed regarding the coupling of wrist and forearm rotations.

## Carpal Ligaments

Tang et al<sup>21</sup> investigated length changes in radiocarpal and midcarpal ligaments of the wrist, in different positions of the DT motion in vivo. They found that from radial extension to ulnar flexion the lengths of volar ligaments (radioscaphocapitate (RSC), long radiolunate (LRL), ulnocapitate (UC) and ulnotriquetral (UT)) significantly decreased, whereas the lengths of the dorsal ligaments (dorsal radiocarpal; portion of the dorsal intercarpal ligament inserting on the trapezoid) increased progressively. The ulnolunate ligament and the portion of the dorsal intercarpal ligament inserting on the scaphoid were shortest in the neutral position. They noted that the four ligaments

(RSC, LRL, UC and UT) that were tighter in radial extension and more lax in ulnar flexion represented both radial and ulnar stabilising structures. It may be that more stability is provided in radial extension at the start of a dynamic motion such as hammering and throwing and less is needed or desirable as the wrist moves into ulnar flexion. In addition, biomechanical studies on the UT ligament have shown that its length is maximum during wrist radial extension, thus this ligament is at risk at the extension phase of DT motion, especially with the forearm in supination<sup>21, 36, 37</sup>. Upal et al<sup>10</sup> have shown that scapholunate (SL) interosseous ligament elongation is minimal as the wrist is positioned along the DT path. It is known that the STT and scaphocapitate ligaments are considered as collateral ligaments of the STT joint that stabilise and control DT motion.<sup>38</sup> However, recent studies demonstrate that these ligaments have very few proprioceptive functions—implying that their principal function is mechanical—in contrast to the dorsal intercarpal ligaments and triquetral-hamate-capitate ligaments, which are thought to constrain the end points of DT motion (i.e. “stops”) via their substantial proprioceptive properties<sup>39</sup>.

## Role of the Muscles

We know that the two wrist motor tendons directly involved in generating swing motion along the DT plane are the flexor carpi ulnaris (FCU) and the extensor carpi radialis brevis and longus (ECRB-L). According to the paper presented by Salva-Coll et al<sup>40</sup>, these two muscles together with the

abductor pollicis longus (APL) are considered as muscles that supinate the midcarpal joint (midcarpal supinators). Since the ligaments crossing the midcarpal joint (ulnar arm of the arquate ligament, SC ligament and STT ligament) are intact, the supination moment will also be transmitted to the proximal row bones. The authors argued that if all carpal supinator muscles contract while the pronators (extensor carpi ulnaris (ECU), flexor carpi radialis (FCR)) relax, the scaphoid is likely to rotate further into supination, a position in which the dorsal SL ligament is better protected. It is therefore reasonable to assume that, by performing a task along the plane of DT motion under the contraction of the supinator muscles of the midcarpal joint, the SL joint is more stable.

In a cadaver study, according to Werner et al<sup>41</sup> during a DT motion, the mean and peak tendon forces of ECRL and FCU were the greatest compared to the corresponding values of ECU, ECRB, APL and FCR tendon forces. Both the peak and mean FCR forces were shown to be significantly less during the DT motion than during wrist flexion-extension, radioulnar deviation or circumduction motions. On average the peak FCR forces were 24% less while the mean FCR forces were 49% less than during the other motions. Conversely the mean and peak FCU forces were significantly greater during a DT motion compared to the other 3 motions (peak forces 86% greater, mean forces 79% greater). These results indicate that to achieve different desired wrist motions different tendon forces are required. Weak musculature may alter the oblique plane of motion necessary to

minimize the tendon forces to achieve a given activity.

### Evolutionary significance

Tang<sup>42</sup> analysed the skeletal specimens of a variety of vertebral animals, ranging from prehistoric and extinct animals to modern primates. The author highlighted five distinct evolutionary changes: first, the single-bone intercalated segment became multiple bony structures between the forearm and the metacarpus; second, a lengthy and a prominent equivalent of the pisiform, which was a dominant feature of the ulnar side of the carpus in animals requiring palmar flexion or weight bearing, evolved to the smallest carpal bone, much less prominent in comparison to those of ancient and giant animals; third, the ratio of the metacarpus to carpus; fourth, the changing roles of the carpal bones from alignment to stability and then to mobility and fifth, the presence of a broad distal part of the radius that causes the overlying tendons to protrude outwards and increases the distance from the tendons to their centers of motion, thereby creating greater moments to maintain or generate the dominant wrist motion pattern which is from radial extension to ulnar flexion, that is DT motion. Evolutionary significance has been ascribed to the DT plane, as it appears that the motion path may be unique to Homo Sapiens, and adaptations in carpal bone development may have abetted tool making, hunting and defensive abilities of early pro-hominids.<sup>43</sup>

### References

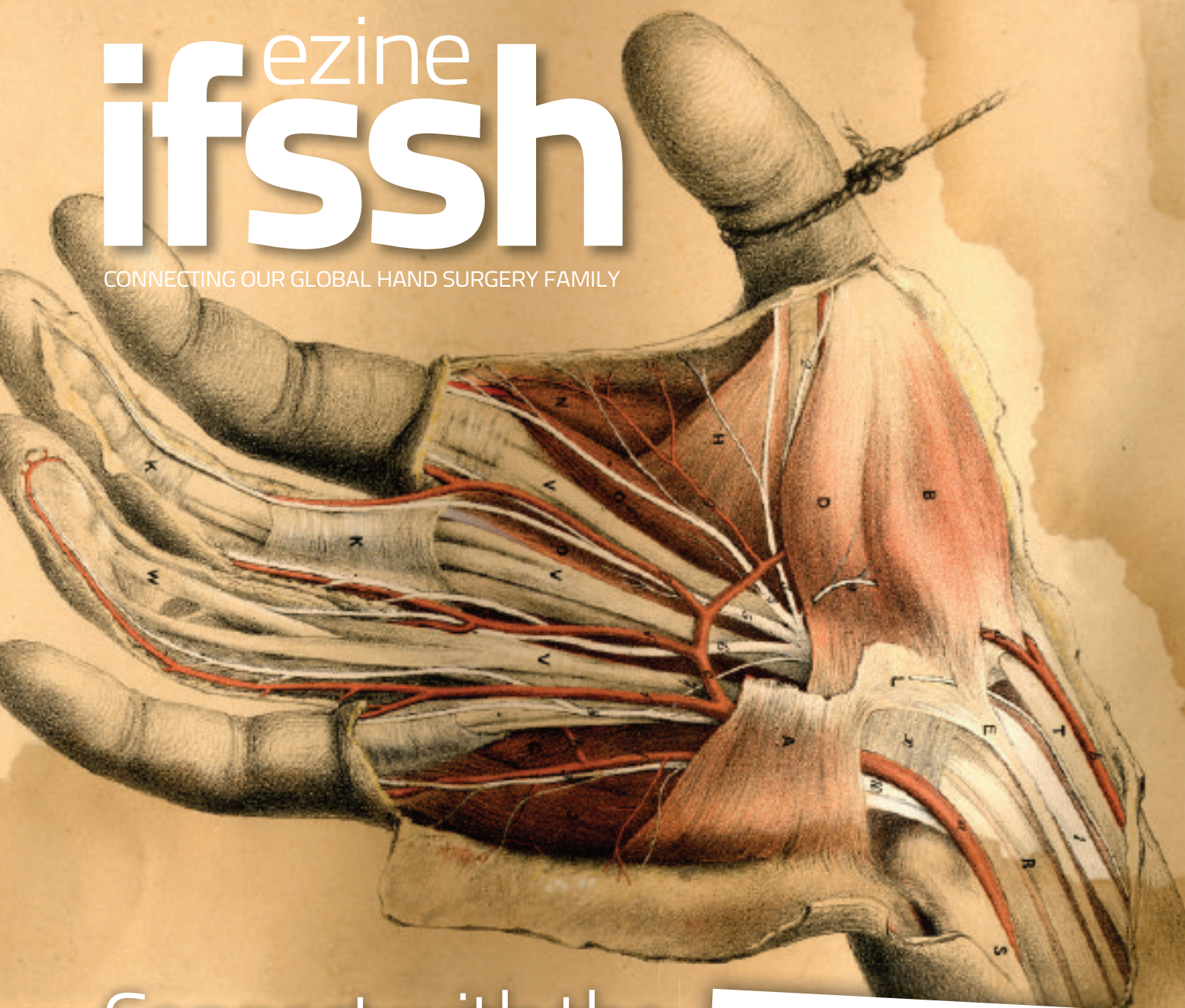1. Moritomo H, Apergis EP, Herzberg G, et al. 2007 IFSSH Committee Report of Wrist Biomechanics Committee: Biomechanics of the So-Called Dart-Throwing Motion of the Wrist. *J Hand Surg (Am)*. 2007;32A(9):1447-1453.
2. Bunnell S. *Surgery of the Hand*. J.B.Lippincott; 1944.
3. Capener NJ. The hand in surgery. *J Bone Joint Surg* 1956; 38B:128-151.
4. Fisk G. Biomechanics of the wrist joint. In: Tubiana R, ed. *The Hand*. Philadelphia: W. B. Saunders, 1981:136-141.
5. Palmer AK, Werner FW, Murphy D, Glisson R. Functional wrist motion: a biomechanical study. *J Hand Surg [Am]* 1985 Jan;10(1):39-46.
6. Saffar P, Seumaan I. The study of the biomechanics of wrist movements in an oblique plane. In: Schwind FA, An KN, Cooney WP, Garcia-Elias M, eds. *Advances in the Biomechanics of the Hand and Wrist*. New York: Plenum Press, 1994:305-311.
7. Crisco JJ, Coburn JC, Moore DC, et al. In vivo radiocarpal kinematics and the dart thrower's motion. *J Bone Joint Surg Am*. 2005;87(12):2729-2740.
8. Werner FW, Green JK, Short WH, Masaoka S. Scaphoid and lunate motion during a wrist dart throw motion. *J Hand Surg (Am)*. 2004;29(3):418-422.
9. Brigstocke GH, Hearnden A, Holt C, Whatling G. In-vivo confirmation of the use of the dart thrower's motion during activities of daily living. *J Hand Surg Eur Vol* 2012 Oct 11
10. Upal MA, Crisco JJ, Moore DC, Sonenblum SE, Wolfe SW. In vivo elongation of the palmar and dorsal scapholunate interosseous ligament. *Journal of Hand Surgery - American Volume*. 2006;31(8):1326-1332.
11. Werner FW, Short WH, Fortino MD, Palmer AK. The relative contribution of selected carpal bones to global wrist motion during simulated planar and out-of-plane wrist motion. *J Hand Surg (Am)*. 1997;22(4):708-713.
12. Ishikawa J, Cooney WP, 3rd, Niebur G, et al. The effects of wrist distraction on carpal kinematics. *J Hand Surg (Am)*. 1999;24(1):113-120.
13. Moritomo H, Murase T, Goto A, Oka K,

- Sugamoto K, Yoshikawa H. In vivo three-dimensional kinematics of the midcarpal joint of the wrist. *J Bone Joint Surg Am* 2006 Mar;88(3):611-21.
14. Leventhal EL, Moore DC, Akelman E, Wolfe SW, Crisco JJ. Carpal and forearm kinematics during a simulated hammering task. *J Hand Surg (Am)*. 2010;35(7):1097-1104.
15. Crisco JJ, Heard WM, Rich RR, Paller DJ, Wolfe SW. The mechanical axes of the wrist are oriented obliquely to the anatomical axes. *J Bone Joint Surg Am*. 2011;93(2):169-177.
16. Li ZM, Kuxhaus L, Fisk JA, Christophel TH. Coupling between wrist flexion-extension and radial-ulnar deviation. *Clin Biomech (Bristol, Avon)* 2005 Feb;20(2):177-83.
17. Carter TI, Pansy BE, Wolff AL, Hillstrom HJ, Backus S, Lenhoff M, et al. Accuracy and Reliability of Three Different Techniques for Manual Goniometry for Wrist Motion. *J Hand Surg [Am]* 2009 Jan 2;34(1422):1428.
18. Bugden B. A proposed method of goniometric measurement of the dart-throwers motion. *J Hand Ther* 2013 Jan;26(1):77-80.
19. Moritomo H, Murase T, Arimitsu S, et al. Change in the length of the ulnocarpal ligaments during radiocarpal motion: possible impact on triangular fibrocartilage complex foveal tears. *Journal of Hand Surgery - American Volume*. 2008;33(8):1278-1286.
20. Arimitsu S, Murase T, Hashimoto J, et al. Three-dimensional kinematics of the rheumatoid wrist after partial arthrodesis. *J Bone Joint Surg Am*. 2009;91(9):2180-2187.
21. Tang JB, Gu XK, Xu J, Gu JH. In vivo length changes of carpal ligaments of the wrist during dart-throwing motion. *J Hand Surg (Am)*. 2011;36(2):284-290.
22. Kamal RN, Rainbow MJ, Akelman E, Crisco JJ. In vivo triquetrum-hamate kinematics through a simulated hammering task wrist motion. *J Bone Joint Surg Am*. 2012;94(12):e85.
23. Carelsen B, Bakker NH, Strackee SD, Boon SN, Mass M, Sabczynski J, et al. 4-D rotational xray imaging of wrist joint dynamic motion. *Med Phys* 2005;32(9):2771-6.
24. Kober C, Gallo L, Zeilhofer HF, Sader RA. Computer-assisted analysis of human upper arm flexion by 4D-visualization based on MRI. *Int J Comput Assist Radiol Surg* 2011 Sep;6(5):675-84.
25. Garcia-Elias M, Alomar Serrallach X, Monill Serra J. Dart-throwing motion in patients with scapholunate instability: a dynamic four-dimensional computed tomography study. *J Hand Surg Eur Vol*. 2013 Apr 8. [Epub ahead of print]
26. Wolfe SW, Syrkin G, Stoecklein HH, Backus S, Wolff AL, Kraszewski A, et al. Altered wrist coupling results in diminished performance of functional tasks. *Proc.Am.Orthop.Assoc*. 2009. 2009.
27. Wolfe SW, Garg R, Kraszewski A, ackus S, ogekku N, enhoff M, et al. Comparison of Wrist Kinematics and Functional Performance between Surgical Treatments for SLAC Wrist. *Proc.Am.Soc.Surgery Hand* 2011, 142. 9-9-2011.
28. Garg R, Kraszewski A, Stoecklein H, et al. Effects of midcarpal arthrodesis on wrist coupling and performance. Paper presented at:2010 Annual Meeting of the American Society of Biomechanics; August 2010; Providence, RI.
29. Calfee RP, Leventhal EL, Wilkerson J, et al. Simulated radioscapholunate fusion alters carpal kinematics while preserving dart-thrower's motion. *J Hand Surg (Am)*. 2008;33(4):503-510.
30. Berkhout MJ, Shaw MN, Berglund LJ, et al. The effect of radioscapholunate fusion on wrist movement and the subsequent effects of distal scaphoidectomy and triquetrectomy. *Journal of Hand Surgery: European Volume*. 2010;35(9):740-745.
31. Garcia-Elias M, Lluch A, Ferreres A, Papini-Zorli I, Rahimtoola ZO. Treatment of radiocarpal degenerative osteoarthritis by radioscapholunate arthrodesis and distal scaphoidectomy. *Journal of Hand Surgery - American Volume*. 2005;30(1):8-15.
32. Moritomo H. The Kinematics and Clinical Implications of the Dart-Throwing motion. In: Slutsky DJ, ed. *Principles and practice of wrist surgery*. Philadelphia, PA: Saunders Elsevier; 2010.
33. Pervaiz K, Bowers WH, Isaacs JE, Owen JR, Wayne JS. Range of motion effects of distal pole scaphoid excision and triquetral excision after radioscapholunate fusion: a cadaver study. *Journal of Hand Surgery - American Volume*. 2009;34(5):832-837.
34. Hug U, Guggenheim M, Kilgus M, Giovanoli P. Treatment of radiocarpal degenerative osteoarthritis by radioscapholunate arthrodesis: long-term follow-up. *Chirurgie de la Main*. 2012;31(2):71-75.
35. Anderton W, Charles SK. Kinematic coupling of wrist and forearm movements. Paper presented at:2012 Annual Meeting of the American Society of Biomechanics; August 16-18 2012; Gainesville, FL.
36. Tay SC, Berger RA, Parker WL. Longitudinal split tears of the ulnotriquetral ligament. *Hand Clinics*. 2010;26(4):495-501.
37. DiTano O, Trumble TE, Tencer AF. Biomechanical function of the distal radioulnar and ulnocarpal wrist ligaments. *Journal of Hand Surgery - American Volume*. 2003;28(4):622-627.
38. Moritomo H, Viegas S.F., Nakamura, K., DaSilva, M.F., Patterson, R.M. The scaphotrapezio-trapezoidal joint. Part 1: An anatomic and radiographic study. *J Hand Surg* , 25A:899-910, 2000.
39. Hagert E, Forsgren S, Ljung BO. Differences in the presence of mechanoreceptors and nerve structures between wrist ligaments may imply differential roles in wrist stabilization. *Journal of Orthopaedic Research*. 2005;23(4):757-763.
40. Salva-Coll G, Garcia-Elias M, Leon-Lopez MT, Llusa-Perez M, Rodriguez-Baeza A. Effects of forearm muscles on carpal stability. *Journal of Hand Surgery: European Volume*. 2011;36(7):553-559.
41. Werner FW, Short WH, Palmer AK, Sutton LG. Wrist tendon forces during various dynamic wrist motions. *J Hand Surg (Am)*. 2010;35(4):628-632.
42. Tang JB. General concepts of wrist biomechanics and a view from other species. *Journal of Hand Surgery: European Volume*. 2008;33(4):519-525.
43. Rohde RS, Crisco JJ, Wolfe SW. The advantage of throwing the first stone: how understanding the evolutionary demands of Homo Sapiens is helping us to understand carpal motion. *J Am Acad Ortho Surg* 2010;18(1):51-8.



# ezine ifssh

CONNECTING OUR GLOBAL HAND SURGERY FAMILY



## Connect with the global profession

The IFSSH ezine is created with the intention of engaging the global hand surgery community and to promote the profession through the sharing of knowledge. In order for the IFSSH ezine to remain relevant and topical, we rely on you, our readers, to:

- Subscribe to receive the ezine  
FREE OF CHARGE 4 times per year
- Submit letters to the editor
- Provide us with feedback about the ezine



# Mallet fingers around the globe: Does one best method for immobilisation and mobilisation exist?

## Part I: Immobilisation

Compiled by Julianne Howell, this article was first published in the January 2014 issue of the American Society of Hand Therapy Times (ASHT Times). Howell asked various therapists from different part of the world to explain their methods of treating patients with a Mallet finger. Contributors: Melissa Hirth, Melbourne, Australia; Gwendolyn van Strien, Den Haag, the Netherlands, Lyn Basini, New York, USA, Dershnee Devan, Johannesburg, South Africa.

According to Doyle's classification of mallet injuries Type 1a-b are closed injuries with or without a fracture<sup>1</sup>. Non-surgical treatment is favoured over surgery following Type 1a-b mallet finger injury<sup>2, 3</sup>. Consensus has been reached that immobilisation is needed to primarily heal these closed bony or tendinous injuries<sup>4</sup>. However, some of the finer details regarding immobilisation are inconclusive as highlighted in Table 1. Hageman et al. indicated that when consensus is

lacking, health care providers fall back to their personal preferences to make treatment recommendations<sup>5</sup>. We suspect, given the inconclusiveness of the evidence for treatment of mallet finger injuries, hand therapists will similarly fall back to personal preference when recommending a cast or orthotic for immobilisation of these injuries.

Hageman et al. noted in addition to personal preference, when our hand surgery colleagues are confronted with inconclusive evidence they fall back to the best available outcome evidence base and involve patient-centered care via shared decision to guide treatment<sup>5</sup>. Unfortunately, much of the literature regarding management of mallet injuries consists of retrospective studies, lacking detail and control of methodology. Given the poor quality of the evidence, hand therapists no doubt may find it difficult to feel confident when making treatment recommendations to patients. Table 2 summarises

some of the evidence issues as well as anatomical/biomechanical observations.

Many reports, including the most recent and well-designed study by Tocco and associates, found no statistically significant difference between a cast and an orthotic in recovery of DIPJ extension<sup>6</sup>. Perhaps in our quest to improve outcome evidence by looking for a single best method to immobilise all mallet fingers, could we be overlooking the possibility that it does not exist? Instead of an approach driven by protocol, a better method may be that both the immobilisation and mobilisation methods be tailored to the patient. To test this hypothesis, hand therapists would need to be skilled in multiple immobilisation techniques, and would be required to merge their examination and assessment findings to decide what is best for each patient. Periodically as healing proceeds, re-assessment of the

patient may require the orthotic or cast to be swapped for another method, immobilisation time lengthened and/or mobilisation exercises slowdown. Additionally a consensus among therapists for the purpose of defining key terms and standardising measurement, would improve the quality of the evidence-base.

Part one of this article is intended to share a variety of immobilisation techniques and tips from hand therapists who work in different corners of the globe and in diverse healthcare settings. Their clinical insights for treatment progression are briefly outlined in Table 3. Part two of this article will elaborate on the techniques and tips these therapists use during the mobilisation phase. The techniques and tips are offered as food for thought to encourage hand therapists and surgeons to re-think their approach in the overall management of Type 1a-b mallet finger injuries.

**“Given the poor quality of the evidence, hand therapists no doubt may find it difficult to feel confident when making treatment recommendations to patients”**

**Table 1**

**Areas of consensus and no consensus in the management of mallet finger injuries (Type 1 a-b)**

#### CONSENSUS

- Immobilisation

#### NO CONSENSUS

- Joints to be immobilised – DIPJ only or PIPJ + DIPJ
- Position of joint(s) – DIP neutral or hyperextension; slight blanching; PIP flexion angle
- Type of device- Orthotic or cast or commercial dorsal, volar, circumferential
- Definition of acute and chronic
- Duration of full time immobilisation – bony and tendinous the same or different
- Patient removal or not
- Effectiveness of night immobilisation
- How long after injury can immobilisation be used and be effective
- Best method(s) to measure outcome – ROM, pain, edema, appearance, etc.
- Effect on outcome - % of articular surface, chronicity, edema, age, PIPJ hyperextension, compliance, etc.
- At what time should the final outcome be measured
- Definition of successful outcome

**Table 2**

**Summary of best available outcome/evidence based and anatomical/ biomechanical observation from which to make treatment recommendations for mallet finger (Type 1 a-b)**

- immobilisation is at least 6 - 12 weeks (sometimes longer)<sup>5-7</sup>
- 0.5mm Terminal Tendon (TT) gap = 10° DIPJ lag; 1mm TT gap = 25° DIPJ lag<sup>8</sup>
- 20% of all patient outcomes have at least a 10° or greater DIP extension lag<sup>9</sup>
- Despite the best compliance return to normal is a challenge<sup>10</sup>
- Skin breakdown, satisfaction with appearance and joint pain/stiffness may be issues <sup>2,4,5</sup>
- Later surgical intervention may be an option<sup>4</sup>



**Table 3**

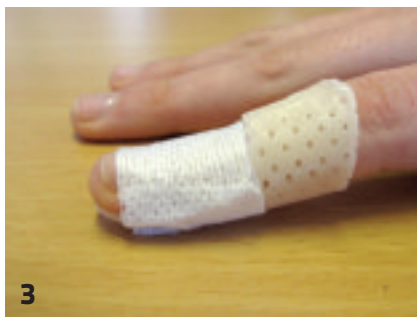
**Questions presented to Hand Therapists from different corners of the globe who work in diverse healthcare settings concerning their decision making for the acute mallet finger (Type 1a-b).**

Questions	Lynn Bassini	Melissa Hirth
What is your ideal time to start immobilisation?	ASAP	0-5d
In reality when does immobilisation typically start?	Varies from same day to weeks later	2-10d
Orthotic or cast?	Cast	Orthotic + tape
DIP only?	Yes	Yes
If yes, DIP neutral or (+) hyperextension?	DIPJ 0° to slight hyperextension no blanching	Bony 0° to +10° Tendon +5° to +15°
When do you immobilise both the DIP + PIP joints?	If PIPJ hyper- extends; add PIPJ to cast in 20-30° flexion	Only if PIPJ hyperextends
Frequency of visits?	1x/wk or as necessary	1x/wk or 1x/2wks
Are tendon/bony mallets immobilised the same?	6wks bony 8wks tendinous If lag 8+wks both	No, at minimum: 6wks bony 8wks tendinous
Do patients remove device to clean?	No	Prefer not until 4wks
How do you decide length of immobilisation?	8 wks after DIP extension lag is 0°	6/8wks if no lag If lag develops reapply orthotic for further 2wks FT
How do you introduce DIPJ motion?	Protected AROM exercises for 2 more wks + removable cast	AROM exercises & Light functional use. Orthotic on for heavy activities & overnight
What criteria do you use to continue weaning from the device?	If no lag develops on recovery of motion, and no pain and return to function	If no lag after 2wks of light functional use & AROM exercises
Do you ever only night splint?	No	Yes
When?	Night and protected splinting go together	2wks further after wean from day use
When do you stop full time immobilisation?	8wks after DIPJ is at 0° extension	If lag persists after 12wks FT orthotic. Negotiate with patient to continue
Define a successful outcome?	<5° lag, minimal edema, no pain +functional fist (1cm to DPC); no forced tight fist	<5° lag or neutral (for those with prior hyper-extension) minimal oedema, no pain, functional fist + satisfied patient
How long post injury would you initiate immobilisation for a chronic mallet finger?	As needed even if it is many years	Preferably no > 6m. Have had a success after 18 years!



Julianne Howell	Gwen van Strien	Dershnee Devan
1-5d No later than 10d	Week 1	Week 1
7-14d; weeks later	Week 1 or, Week 6 when referred to our clinic, after first treatment failed elsewhere	Week 1-2
Orthotic +tape	Cast	Orthotic + elastic tape
No	Yes +5° to +10°	Yes neutral
Standardly PIPJ 20-30° flexion DIPJ +0° to +15°	If PIPJ is hypermobile	Only if there is pathology /hyperextension of the PIPJ
1x/wk; PRN	Week 1-2 twice/wkly Thereafter, 1x/wk or 1x/2wk	1x/wk
Yes	Yes	Yes Unless post-surgical
Prefer not until 4wks	No	Yes Elastic tape remains in situ
6-8 wks after DIP extension lag is 0-5°. PIP motion of -30° to 90° flexion is initiated at 4wks	8wks if no lag If lag develops between wk 8 to 12 return to FT cast for 2-4 more wks	4 wks is standard if no lag. If lag- orthotic continued 2 weeks further
Protected AROM exercises 2 wks further + orthotic	Limited protected AROM for 2 more wks + replace cast with a removable orthotic	Discontinue daytime orthotic continue elastic tape, exercises and light ADL
After 2wks protected motion and no lag or ↑lag	After 2wks protected motion and no lag or ↑lag	Active DIPJ extension to 0°
Rarely	Yes	Yes
DIPJ painful or fails to keep full passive extension	As many weeks as needed after weaned of daytime splint	At wk 4 when day splinting is discontinued, for an additional 2 wks
No increase in lag. Will go as long as 16wks w patient consent	No increase in lag	At 4wks if no lag
<5° lag, minimal edema, no pain, functional fist + patient satisfied	<5° lag, minimal edema, no pain, functional fist (full fist may take a year to achieve.	0° extensor lag
Anytime, what is there to lose if the patient is willing?	Up to 6months	Recommend it as a first option. Chronicity will prolong treatment progression

## Hand therapist: Melissa Hirth



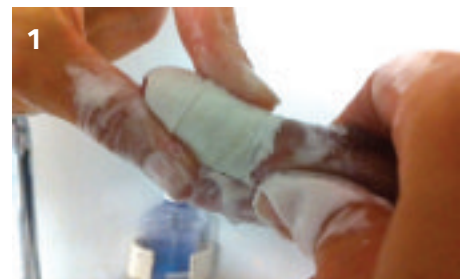**Figure 1:** Tip 1: To avoid excessive stretching of the plastic wait until it has started to become opaque again before pinching above the fingertip & pulling the plastic up to achieve DIPJ hyperextension.

**Figure 2a:** Tip 2a: To enable full PIP joint motion and to avoid distal splint migration cut a small arc in the proximal volar surface of the splint, and flare ever so slightly by dipping the proximal end 2-3 mm in the hot water and use your fingers to smooth.

**Figure 2b:** Tip 2b: To stop the seam from splitting dip the plastic into hot water at the proximal seam and gently stretch these small tabs to place one on top of the other & squeeze together.

**Figure 3:** Tip 3: To maintain hyperextension, avoid rubbing or slippage, & assist oedema management via effectively creating a circumferential orthotic place a strip of tape in the 'no-stretch' direction firmly adjacent to the seam & press the finger down into the splint.


## Hand therapist: Lynn Bassini



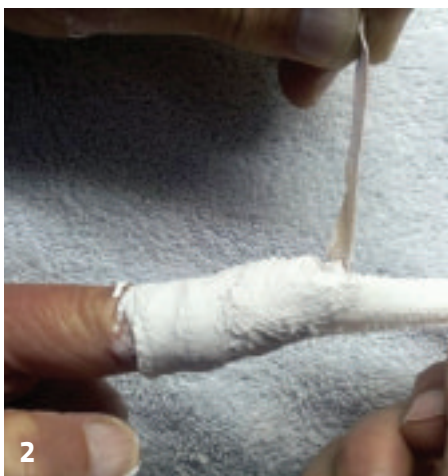**Figure 1:** Tip 1: Do this at a sink, use about one-third of a roll of narrow plaster. Wet the roll and squeeze excess water out of roll, cool water lengthens the time you have to work the plaster. Wrap securely but not too tight around the finger leaving the distal tip exposed to check for color and feeling. While doing this ask the patient to relax the PIP joint while the therapist pushes the DIPJ into (hyper) extension. If the PIPJ hyper-extends, include the PIPJ in the cast and flex it to 20/30°.

**Figure 2:** Tip 2: once the cast is hard, ask the patient to flex the PIPJ to assure motion is comfortable and the cast does not slip off. Wrap the cast and extend the wrap more proximal with a self-adherent wrap to keep it clean and anchor it.

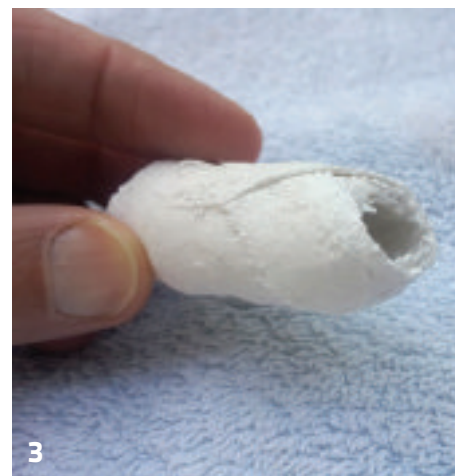## Hand therapist: Gwen van Strien



**Figure 1:** Tip 1: Place a length of cloth-like tape along the volar middle and distal phalanx to pull the DIPJ into the precise position of hyperextension. The patient holds the tape, so the therapist can mold with both hands. Use 4 strips of plaster (2" wide; 5" long); fold each strip in half lengthwise. Dip strips in water, lay out on a paper towel, and lightly stroke each strip to remove excess water making it more paste-like. Carefully wrap in a circular-manner and smooth. Start with the 1st strip proximally, the 2nd strip distally, and the 3rd to make it "neat" (at times another circular strip may be needed). Save the 4th strip for finishing/reinforcing.



**Figure 2:** Tip 2: There is no need to push the DIPJ into extension when molding (pressure points), because the patient is holding the tape. Place the 4th strip at an angle, crisscrossing over the dorsal side of the cast; to add reinforcement; make certain the distal nail is visible. The cast sticks to the tape, so it will not slip off.



**Figure 3:** Tip 3: For this picture, the crisscrossed strip was not smoothed for identification. Cut the ends of the exposed tape. Smooth the plaster away from the PIPJ flexion crease. A coat of clear fingernail polish makes it more water resistant. Round tipped scissors work well for removal; start at proximal-volar aspect, nip away along the line of the tape distally, and peel away the cast and tape.

## Hand therapist: Julianne Howell



**Figure 1:** Tip 1: Attach a strip of cloth-like tape to the volar PIPJ then up & over the end of the fingertip; have the patient hold the tape to keep DIPJ (hyper) extension. The therapist now has two working hands to mold the plastic; ask the patient to lower the angle of the tape as the plastic is molded over the dorsum of the finger. The PIPJ remains in neutral extension.

**Figure 2 a&b:** Tip 2a: While the plastic is still warm, carefully and quickly trim off the excess plastic on both sides of the orthotic to make seams.

Tip 2b: As the plastic cools press up lightly on the volar fingertip for DIPJ position and flex the PIPJ to the desired position.

**Figure 3:** Tip 3: Remove the orthotic for finishing, the tape will remain on the finger- have the patient hold the tape to maintain DIPJ position. Trim seams to allow adjustability and secured with cloth-like tape; encourage the patient to add tape as needed to snug the seams together between visits.

### References

1. Doyle JR. Extensor tendons: Acute injuries in Green DP, editor, *Operative hand surgery* 4ed, New York, NY, Churchill Livingstone 1999.
2. Geyman JP, Fink K, Sullivan SD. Conservative versus surgical treatment of mallet finger: a pooled quantitative literature evaluation. *J Amer B Fam Pract* 1998;11:382-390.
3. Kalainov DM, Hoepfner PE, Harigan BJ, et al. Non-surgical treatment of closed mallet finger fractures. *J Hand Surg* 2005; 30A:580-586.
4. Handoll HH, Vaghela MV. Interventions for treating mallet finger injuries. *Cochrane Database Syst Rev* 2004; (3); CD004574 (updated 2008).
5. Hageman M, Guitton TG, Ring D. How surgeons make decisions when the evidence is inconclusive. *J Hand Surg* 2013;38A:1202-1208.
6. Tocco S, Bocolari P, Landi A, et al. Effectiveness of cast immobilisation in comparison to the gold-standard self-removal orthotic intervention for closed mallet fingers: A randomised clinical trial. *J Hand Ther* 2013; (26)3; 191-201.
7. Pratt AL. Is eight weeks' immobilisation of the distal interphalangeal joint adequate treatment for acute closed mallet finger injuries of the hand? A critical review of the literature. *Br J Hand Ther* 2004;9;4-10.P
8. Patel MR, Sheklar SD, Bassini-Lipson L. Conservative management of chronic mallet finger. *J Hand Surg* 1986;11A:570-573.
9. Schweitzer TP, Rayan GM. The terminal tendon of the digital extensor mechanism: Part 1 anatomic study. *J Hand Surg* 2004; 29A: 898-902.
10. Strauch RJ. Extensor tendon injuries. In: Green D, Hotchkiss R, Pederson W, editors. *Green's operative hand surgery*. 6th ed. New York: Elsevier, Churchill Livingstone; 2001. p 159-188.
11. Groth GN, Wilder DM, Young VL. The impact of compliance on the rehabilitation of patients with mallet finger injuries. *J Hand Ther* 1994; 7; 21-24.

## About the author

Julianne W Howell, PT, MS, CHT, Samaritan Health Services, Corvallis, Oregon, USA. Email Julianne at [julianneh@earthlink.net](mailto:julianneh@earthlink.net)



# Basic science of bone healing

## USA

In a recent article published in *Hand Clinics* Dr Michael Darowish led a review of the biology involved in the regeneration of new bone after fracture, and factors influencing bone healing, including diabetes, smoking, NSAID use, and bisphosphonates. He talked to the IFSSH ezine about his investigation: "I was lucky enough to spend a year during my residency working in the orthopaedic research lab at the University of Rochester under the direction of Dr Regis O'Keefe. Dr Sathyendra (my co-author) spent a year working in the Penn State orthopaedic research lab with Dr Henry Donahue. So we both were lucky to be exposed to the basic science side of orthopaedics during our training. Thus, when Dr Lawton approached me to provide an article for *Hand Clinics*, the fracture healing article was a natural fit. I have tried to incorporate my understanding of basic science into my clinical practice, applying easy and practical steps into patient management," he commented.

For Darowish, some of the most interesting points that the review highlighted about bone healing was that understanding the factors that are within the control of the physician and the patient is essential in optimising bone healing. "NSAID use, smoking, utilisation of bone stimulators; these are all things we as surgeons frequently overlook but can significantly impact our patients' outcomes," he explained.

## **"Being mindful of metabolic, endocrine, or external influences on healing can only benefit the patient"**

He further believes that understanding the effects of bisphosphonates on fracture healing is not well understood. "We are all aware of the subtrochanteric femur fractures which were caused by 'frozen bone disease' from taking bisphosphonates for too long, but understanding that they may impact the speed of healing in your patients may change your management – longer immobilisation, more cautious rehabilitation, etc," he added.

"I think that many of us underappreciate the influence of these outside factors. I also think that metabolic influences on bone healing – vitamin D deficiency, poor nutrition, etc, are frequently ignored," he continued, adding that Brinker et al showed that in patients with fracture nonunion in the setting of a well done surgery, nearly 84% of their patients were found to have either a metabolic or endocrine abnormality. According to him, that being mindful of these issues earlier in the course of treatment can potentially benefit patients greatly.

The fundamental principles that hand surgeons and therapists should understand about bone healing include that different methods of fracture treatment will yield different forms of healing – casting or pinning will heal by endochondral ossification, where a rigid plate and screw construct will heal by primary bone healing – and understanding how to interpret radiographs accordingly.

"Being mindful of metabolic, endocrine, or external influences on healing can only benefit the patient, and being proactive in checking for these factors rather than waiting for a complication to occur before evaluation or discussion of these issues can prevent some of these problems. Some of these factors are out of our control (age, renal disease), but some can be easily changed or treated. It really doesn't add much time to your interactions to discuss these issues. And while many of us are not comfortable managing these issues, we can obtain some basic screening laboratories and then appropriately refer the patients for further care if it is indicated," he concluded.

## **JOURNAL REFERENCE**

*Hand Clinics*, Volume 29, Issue 4 , Pages 473-481, November 2013  
[http://www.hand.theclinics.com/article/S0749-0712\(13\)00057-7/abstract](http://www.hand.theclinics.com/article/S0749-0712(13)00057-7/abstract)

# Thoughts on patient contact: the doctor never even touched me!

Increasing age and infirmity inevitably introduces you to more clinical colleagues than your previous social circle could ever provide. In recent years I have developed a variety of complaints which ensure my intermittent attendance at a disturbingly large number of hospital clinics. I feel I am now on first name terms with most of the staff within the large hospital in which I work. Those wishing to audit the hospital's performance should save themselves time and money, put away their clip boards and simply take me out for a decent lunch. I can tell them everything they need to know.

Against that introductory background herewith some thoughts on the potentially explosive matter of health care professionals touching their patients, and whether that form of patient contact has added value over contact arising from simple clinical necessity. Is patient contact therapeutically beneficial and, within careful limits, to be encouraged - or has respect for a patient's 'space' reached such a level that touching patients should be, where possible, avoided?

Who touches patients? In many departments it is the nurses and

technicians who touch patients. The physicians (particularly) touch their patients relatively infrequently, particularly if they work in a sophisticated health care system which provides them with so much detailed internal information through the wide variety of scans which are now available and so frequently requested. When I was a cardiology trainee, many years ago, I remember the duties to be a 'hands-on' experience; it was the only way to gather the limited clinical evidence that was at the time available. Touching the patient is now for physicians less necessary and, in my experience, more rarely employed.

Hand surgeons touch patients. I've never found it possible to do the job without touching and testing the patients hand function. There are of course cultural sensitivities to be respected in this area. However I cannot recall any patient exhibiting reluctance to a hand examination during my career. I believe I have sufficient sensitivity to be aware of any possible reluctance or offence in such circumstances.

Do patients like being touched by their doctors? I suspect, within carefully chosen parameters, they do. It can represent solidarity, rapport with

the patient and empathy with their situation. I have certainly taken comfort from doctor contact over the last few years. It has a long history to commend it, stretching back to the physicians of Greece and Arabia. The laying on of hands was part of a physician's practice. I accept this may be an area where attitudes could well be changing. Over the last 20 years patients have become more concerned about preserving the space around them and may be less tolerant to that space being invaded. Medical students are now taught to ask permission to touch their patients, a practice that was never felt necessary in the past. It will be interesting to see how these attitudes continue to evolve. Perhaps society now prefers more detachment from their doctors - a drier, distant, more technical response.

PS. I know what you're thinking - there goes another medical dinosaur - trotting off into the sunset!

**Frank Burke**  
*Archivist IFSSH*



# Pioneers in Hand Surgery

## Douglas W. Lamb, M.B., F.R.C.S.Ed.


Douglas Lamb, a native of Edinburgh, Scotland, received his M.B. and Ch.B. degree from the University of Edinburgh. He was a Surgeon Lieutenant in the Royal Navy from 1945 to 1947 and became a fellow of the Royal College of Surgeons of Edinburgh in 1948. Following two years of general surgery training at the Western General Hospital, Edinburgh, he completed his orthopaedic surgery training at the University of Edinburgh, Royal Infirmary and Princess Margaret Rose Orthopaedic Hospital (1950-1960) where he later served as a Consultant Orthopaedic Surgeon (1960-1988). In 1959, he did an orthopaedic surgery fellowship at the Rancho Los Amigos Orthopaedic Hospital and a hand surgery fellowship with Dr Joseph Boyes in Los Angeles, California.

Lamb's appointments with the British Society for Surgery of the Hand have included Founder Member (1969), Honorary Secretary (1969 to 1976), President (1976 to 1977), Member of Council (1978 to 1992), Chairman of the Education and Training Committee (1986 to 1991), and Delegate to the International Federation of Societies for Surgery of the Hand. He has chaired the IFSSH Committees on Rehabilitation – Prosthetics/Orthotics (1979 to 1989) and on Congenital Abnormalities (1979 to 1992), and has been the President of this prestigious Federation

from 1989 to 1992. Mr. Lamb has been a member of the Overseas Examination Teams to Malaysia, Burma, Hong Kong and Saudi Arabia. He has served the Royal College of Surgeons of Edinburgh as Member of Council (1978 to 1988), Director of Overseas Doctors Training Scheme (1988 to 1990), and examiner in anatomy, surgery and orthopaedic surgery.

Lamb is a fellow of the British Orthopaedic Association and Honorary Member of the American, French, South African, and Scandinavian Societies for Surgery of the Hand. His impressive career as a hand surgeon, organiser, educator and author has included appointments as Chairman of the Editorial Board of the Upper Limb and Hand Series (Churchill Livingstone), member of the Editorial Committees of the Journal of Hand Surgery (British Volume) and of the International Medical Society of Paraplegia.

He has organised the Annual Instructional Course in Surgery of the Hand at the Princess Margaret Rose Orthopaedic Hospital for the past 15 years. He gave the Founder Lecture of the American Society for Surgery of the Hand (1975), the Charles Bell lecture (1981), and the Mason Brown Memorial Lecture (1983) at the Royal College of Surgeons, Edinburgh, and the Hugh Owen Thomas Lecture at the University of Liverpool (1984). He received the Farquharson Award for



Teaching Anatomy from the Royal College of Surgeons (1984) and the Lawrence Poole Prize for Rehabilitation from the University of Edinburgh (1983).

Lamb has published a number of books on the practice of hand surgery, including paralysis, trauma, flexor tendon injuries and upper limb deficiencies in children.



## Luis Gómez Correa, M.D.

Dr Gómez graduated from the University of Mexico Medical School in 1943. He trained in general surgery and traumatology and later studied plastic surgery. While appointed surgeon to the slaughter houses of Mexico, he was exposed to a great volume of hand trauma cases and developed a keen interest in this field. Starting in 1953 he studied hand surgery under the direction of Mario Gonzalez Ulloa and many visiting professors including J. William Littler, Michael L. Mason, W.L. White, Bob Chase, Sylvester Carter, Earle Peacock, Eugene Kilgore and others. Dr Gómez was appointed general surgeon and plastic surgeon at the La Raza General Hospital (1958) where he took care of severe trauma cases and performed his first successful hand replantation in 1967.

Gómez, a dedicated surgeon and teacher, played a crucial role in the dissemination of knowledge of hand surgery through Mexico, Central America and the Caribbean. In association with the Department of Labor Medicine of the Mexican Social Security, he has organised a series of hand trauma courses that have been held since 1961 in most major cities of Mexico. He also conducted hand surgery courses throughout most Latin American countries, the first having been held in Caracas, Venezuela in 1963. Dr Gómez was

appointed Professor of Plastic Surgery at the La Raza Hospital in 1968 and at the University of Mexico in 1971. He served as Consultant in plastic and hand surgery for the emergency hospitals of Mexico City (1974 to 1976) and has been working as full-time hand surgeon at the Hospital 20 de Noviembre since 1977.

In 1980, the University of Mexico officially recognized a one-year hand surgery training program for surgeons having completed their plastic, general or orthopaedic surgery residencies. Dr Gómez, as director of the only hand surgery program available in Mexico, has trained 52 hand surgeons. In co-operation with Dr Luis Badell from Caracas, Venezuela, he founded the Caribbean Society for Surgery of the Hand in 1968. In 1976, he organized the first Panamerican Congress for Hand Surgery in Mexico City. Dr Gómez is the author of a number of publications on hand trauma and has translated into Spanish a series of hand surgery videotapes made available by the American Society for Surgery of the Hand.

Gómez was President of the Mexican Society of Plastic Surgeons (1959-1962) and became Honorary Member of the American Society for Surgery of the Hand in 1975. He received the Gold Medal from the Mexican Social Security (1969), was nominated emeritus Member of the



Mexican Academy of Surgeons (1991) and honoured as Pioneer Professor by the International Federation of Ibero Latin American Societies of Plastic Surgery.

# Journal Highlights

Below is a selection of contents pages from the latest issues of the following leading hand surgery journals. Hover your mouse over each article heading and click to go to the online journal

## Journal of Wrist Surgery **Issue 01 Volume 03 • February 2014**

- Radiographic Predictors of DRUJ Instability with Distal Radius Fractures
- Distal Radius Malunion and Forearm Rotation: A Cadaveric Study
- Radiographic and Arthroscopic Assessment of DRUJ Instability Due to Foveal Avulsion of the Radioulnar Ligament in Distal Radius Fractures
- Influence of Ulnar Translation of the Radial Shaft in Distal Radius Fracture on Distal Radioulnar Joint Instability
- Defining Residual Radial Translation of Distal Radius Fractures: A Potential Cause of Distal Radioulnar Joint Instability
- Revision Wrist Arthroscopy after Failed Primary Arthroscopic Treatment
- RSL Fusion with Excision of Distal Scaphoid and Triquetrum: A Cadaveric Study
- One Size Does Not Fit All: Distal Radioulnar Joint Dysfunction after Volar Locking Plate Fixation
- Ectopic Bone Formation after Medial Femoral Condyle Graft to Scaphoid Nonunion
- Osteotomy for Sigmoid Notch Obliquity and Ulnar Positive Variance
- Fixation of Distal Ulna Fractures Associated with Distal Radius Fractures Using Intrafocal Pin Plate
- Important Anatomical Relationships of the Posterior Interosseous Nerve in the Distal Forearm for Surgical Planning: A Cadaveric Study

---

## Hand Clinics **Latest issue is: Volume 30 • Issue 2 May 2014**

- An Evolutionary Perspective on the History of Flap Reconstruction in the Upper Extremity
- Anatomy and Physiology of Perforator Flaps of the Upper Limb
- Local Flaps of the Hand
- Flap Reconstruction of the Elbow and Forearm: A Case-Based Approach
- Free Muscle Flaps for Reconstruction of Upper Limb Defects
- Indications, Selection, and Use of Distant Pedicled Flap for Upper Limb Reconstruction
- Free Skin Flap Coverage of the Upper Extremity
- Refinements and Secondary Surgery After Flap Reconstruction of the Traumatized Hand
- Optimizing Functional and Aesthetic Outcomes of Upper Limb Soft Tissue Reconstruction
- Dermal Skin Substitutes for Upper Limb Reconstruction: Current Status, Indications, and Contraindications

## Hand **Volume 9 – Issue 1, March 2014**

- Rehabilitation following hand transplantation
- Metacarpal fractures: treatment and complications
- A hand surgeon's guide to common onychodystrophies
- Surgeon perspectives on alternative nerve repair techniques
- Prospective randomized comparison of single-incision and two-incision carpal tunnel release outcomes
- Concomitant endoscopic carpal and cubital tunnel release: safety and efficacy
- Carpal tunnel release using the Paine retinaculotome inserted through a palmar incision
- Effects of multiple injections of hypertonic dextrose in the rabbit carpal tunnel: a potential model of carpal tunnel syndrome development
- A role delineation study of hand surgery in the USA: assessing variations in fellowship training and clinical practice
- The correlation of phrases and feelings with disability
- The association of education level on outcome after distal radius fracture
- The impact of demographic factors and comorbidities on distal radius fracture outcomes
- MRI Detection of Forearm Soft Tissue Injuries with Radial Head Fractures
- Reconstruction of swan neck deformities after proximal interphalangeal joint arthroplasty
- The Effect of Pulley Reconstruction on Maximum Flexion, Bowstringing, and Gliding Coefficient in the Setting of Zone II Repair of FDS and FDP: a Cadaveric Investigation
- Importance of proximal A2 and A4 pulleys to maintaining kinematics in the hand: a biomechanical study
- Utility of MRI for diagnosing complete tears of the collateral ligaments of the metacarpophalangeal joints of the lesser digits
- Computed tomography for suspected scaphoid fractures: comparison of reformations in the plane of the wrist versus the long axis of the scaphoid
- Idiopathic avulsion of the flexor pollicis longus: Case report and review of the literature
- Oral smoothened inhibitor for advanced basal cell carcinoma of the hand: a case report

## Journal of Hand Surgery (European Volume) **May 2014 J Hand Surg Eur Vol 39, Issue 4**

- Dart-throwing motion in patients with scapholunate instability: a dynamic four-dimensional computed tomography study
- Unifying model of carpal mechanics based on computationally derived isometric constraints and rules-based motion – the stable central column theory
- Dynamic motion analysis of dart throwers motion visualized through computerized tomography and calculation of the axis of rotation
- In-vivo confirmation of the use of the dart thrower's motion during activities of daily living
- Contact areas of the scaphoid and lunate with the distal radius in neutral and extension: correlation of falling strategies and distal radial anatomy
- In vivo length changes of wrist ligaments at full wrist extension
- Three-dimensional analysis of the palmar plate and collateral ligaments at the proximal interphalangeal joint
- The connective tissue and ligaments of the distal interphalangeal joint: a review and investigation using ultra-high field 16.4 Tesla magnetic resonance imaging
- Long-term outcome (22–36 years) of silicone lunate arthroplasty for Kienböck's disease
- Scaphocapitate arthrodesis for treatment of late stage Kienböck disease
- Secondary displacement of distal radius fractures treated by bridging external fixation
- Corrective distal radius osteotomy following fracture malunion using a fixed-angle volar locking plate
- Acute calcium deposits in the hand and wrist; comparison of acute calcium peritendinitis and acute calcium peri-arthritis

## Hand Surgery: Asia Pacific **Volume 19, Number 1, 2014**

- Reliability of the hand20 questionnaire: comparison with the 36-item short-form health survey
- Brachial plexus injuries: diagnosis performance and reliability of everyday tools
- Risk factors for dislocation of the ulnar nerve after simple decompression for cubital tunnel syndrome
- Comparison between cast immobilization versus volar locking plate fixation of distal radius fractures in active elderly patients, the Asian perspective
- Proximal ulnar stump stability after using the pronator quadratus muscle transfer combined with the Sauvé-Kapandji procedure in rheumatoid wrist
- Early results of combined palmar-dorsal scapholunate ligament reconstruction
- The modified Brunelli procedure for scapholunate instability: a single centre study
- Clinical characteristics of neuropathic pain in patients with carpal tunnel syndrome
- The effect of ultrasound guided steroid injection on progression to surgery in thumb cmc arthritis
- A prospective randomized controlled trial of controlled passive mobilization vs. Place and active hold exercises after zone 2 flexor tendon repair
- The McCash technique for Dupuytren's disease: our experience
- Simultaneous four finger metacarpophalangeal joint fusions – indications and results
- Outcome of pyrocarbon proximal interphalangeal joint replacement
- External fixation of the hand: a simple approach to comminuted proximal interphalangeal joint fractures
- The radial nerve palsy caused by embedding in the humeral shaft fracture — a case report
- Malignant schwannoma of the radial nerve with unusual presentation: a case report
- Acute bilateral spontaneous forearm compartment syndrome
- Intraneural malignant granular cell tumor — report of an extremely rare tumor in a child
- A case report of a giant forearm lipoma causing anterior interosseous nerve palsy after fracture of the distal radius
- Compressive neuropathies related to ganglions of the wrist and hand
- Osteolysis with secondary arthritis of the scaphotrapeziotrapezoid joint in Hajdu-Cheney syndrome: a case report
- Extensor tendon dislocation after end-to-side transfer in a rheumatoid patient
- Simple surgery to improve flexion deficit resulting from mal-union of fracture neck of the proximal phalanx — a case report
- Synovial chondromatosis affecting a digital proximal interphalangeal joint
- Trichilemmal cyst of the third fingertip: a case report
- Vascularized nail transfer from non-replantable digit: a case report
- Fixation of an ulnodorsal fragment when treating an intra-articular fracture in the distal radius
- The path of screw insertion for stabilization of the scapholunate joint: a cadaveric study

## Journal of Hand Therapy **Volume 27, Issue 2, April-June 2014**

- Surgical and therapy update on the management of Dupuytren's disease
- Current uses of botulinum toxin A as an adjunct to hand therapy interventions of hand conditions
- Advances in nerve transfer surgery
- Upper extremity limb loss: Functional restoration from prosthesis and targeted reinnervation to transplantation
- Evolution of basal joint arthroplasty and technology in hand surgery
- The use of the Artelon CMC Spacer for osteoarthritis of the basal joint of the thumb
- Thumb basal joint: Utilizing new technology for the treatment of a common problem
- Update on the surgical treatment for rheumatoid arthritis of the wrist and hand
- SSC management – In person appointments and remote therapy (SMART): A framework for management of chronic hand conditions
- A Physician's perspective on volunteering overseas... It's not all about sharing the latest technology
- Clinical Commentary in Response to "A physician's perspective on volunteering overseas... It's not all about sharing the latest technology"



# Journal of Hand Surgery: American volume

**Volume 39, Issue 5, (May 2014)**

- Arthroscopic Reduction of Comminuted Intra-Articular Distal Radius Fractures With Diaphyseal-Metaphyseal Comminution
- The Influence of Surgeon Age on Distal Radius Fracture Treatment in the United States: A Population-Based Study
- Distal Radius Volar Locking Plate Design and Associated Vulnerability of the Flexor Pollicis Longus
- Relationship of Bone Mineral Density of Spine and Femoral Neck to Distal Radius Fracture Stability in Patients Over 65
- Volar Percutaneous Screw Fixation of the Scaphoid: A Cadaveric Study
- Vascularized Bone Grafting and Distal Radius Osteotomy for Scaphoid Nonunion Advanced Collapse
- Rotational Stability for Intercarpal Fixation Is Enhanced by a 4-Tine Staple
- Bicolumnar Intercarpal Arthrodesis: Minimum 2-Year Follow-Up
- The Effect of Soft Tissue Distraction on Deformity Recurrence After Centralization for Radial Longitudinal Deficiency
- Early Results of Anterior Elbow Release With and Without Biceps Lengthening in Patients With Cerebral Palsy
- The Effect of Asymmetric Core Suture Purchase on Gap Resistance of Tendon Repair in Linear Cyclic Loading
- Attrition or Rupture of Digital Extensor Tendons Due to Carpal Boss: Report of 2 Cases
- Metastases to the Hand and Wrist: An Analysis of 221 Cases
- Chondroblastoma-Like Chondroma of the Hand: Case Report
- Superficial Angiomyxoma of the Thumb Mimicking a Malignant Bone Tumor: Case Report
- Nerve Transfer From Triceps Medial Head and Anconeus to Deltoid for Axillary Nerve Palsy
- Patient Satisfaction and Self-Reported Outcomes After Complete Brachial Plexus Avulsion Injury
- Factors Influencing Infection Rates After Open Fractures of the Radius and/or Ulna
- Povidone-Iodine Soaks for Hand Abscesses: A Prospective Randomized Trial

# Upcoming events

## European Voice of Plastic Surgery (ESPRAS)

6-11 July 2014

Edinburgh, Scotland

[www.espras2014.org](http://www.espras2014.org)

ESPRAS 2014 will offer delegates the opportunity to experience a truly multi-disciplinary, multi-national and multi-cultural programme with world leading experts across the entire spectrum of disciplines associated with Plastic, Reconstructive and Aesthetic surgery.

## 6th European Plastic Surgery Research Council (EPSRC) 2014

21 – 24 August 2014

Hamburg, Germany

[www.epsrc.eu](http://www.epsrc.eu)

The EPSRC is a non-profit organisation managed by and for the benefit of the young plastic, reconstructive and aesthetic surgery research community. We are kindly requesting that all European national societies announce our next meeting aimed at young plastic surgery researchers. It will offer an exciting opportunity for young plastic surgery researchers to discuss their latest work and future challenges in a uniquely informal, interactive format for basic science and clinical outcome research. The EPSRC meeting will provide a valuable means of disseminating information and ideas in a way that cannot be achieved through the usual channels of communication - publications and presentations at large scientific meetings. The conference official language is English.

28, al 30 de Agosto de 2014 | Hotel Pozos Colorados | Santa Marta - Colombia

### XXX Congreso Nacional de la Asociación Colombiana de Cirugía de la mano

**INVITADOS**  
Dr. Michel Merle.  
Francia  
Dr. David Slutsky.  
Estados Unidos  
Dr. Juan Gonzalez del Pino.  
España

**Valor inscripciones**

Miembros al día ASOCIMANO y ASCOTEMA	\$ 550.000
No miembros	\$ 700.000
Residente, estudiante y médico General	\$ 400.000
Cirujano plástico, ortopedista, médico General y FT o TO internacional	\$ 300 USD

Inscripción de trabajos libres, de ingreso y de poster,  
hasta: **30 de Mayo de 2014**  
Entrega de trabajos libres, de ingreso y poster,  
hasta: **30 de Junio de 2014**

Informes:  
E-mail: [secretaria@asocimano.org](mailto:secretaria@asocimano.org)  
[www.asocimano.org](http://www.asocimano.org)  
Celular: 316 6164988



## Second International Symposium on Arthrogryposis

**17-18 September 2014, St Petersburg, Russia**

**<http://amc-2014.org/>**

We have pleasure in inviting you to join us to the SECOND INTERNATIONAL SYMPOSIUM ON ARTHROGRYPOSIS «UPDATES FROM AROUND THE WORLD» which will be held in Saint-Petersburg, Russia on 17th and 18th September 2014. The faculty will consist of senior clinicians from all over the world with particular expertise in the management of all aspects of the care of children and adults with Arthrogryposis including geneticists, neuromuscular paediatricians, surgeons and rehabilitation experts. This is a unique opportunity to discuss the difficulties of managing this complex condition. One of the world's most beautiful cities, St Petersburg has all the ingredients for an unforgettable travel experience. The city offers an extraordinary history and rich cultural traditions, which have inspired and nurtured some of the modern world's greatest literature, music, and visual art. From the mysterious twilight of the White Nights to world-beating opera and ballet productions on magical winter evenings, St Petersburg charms and entices in every season

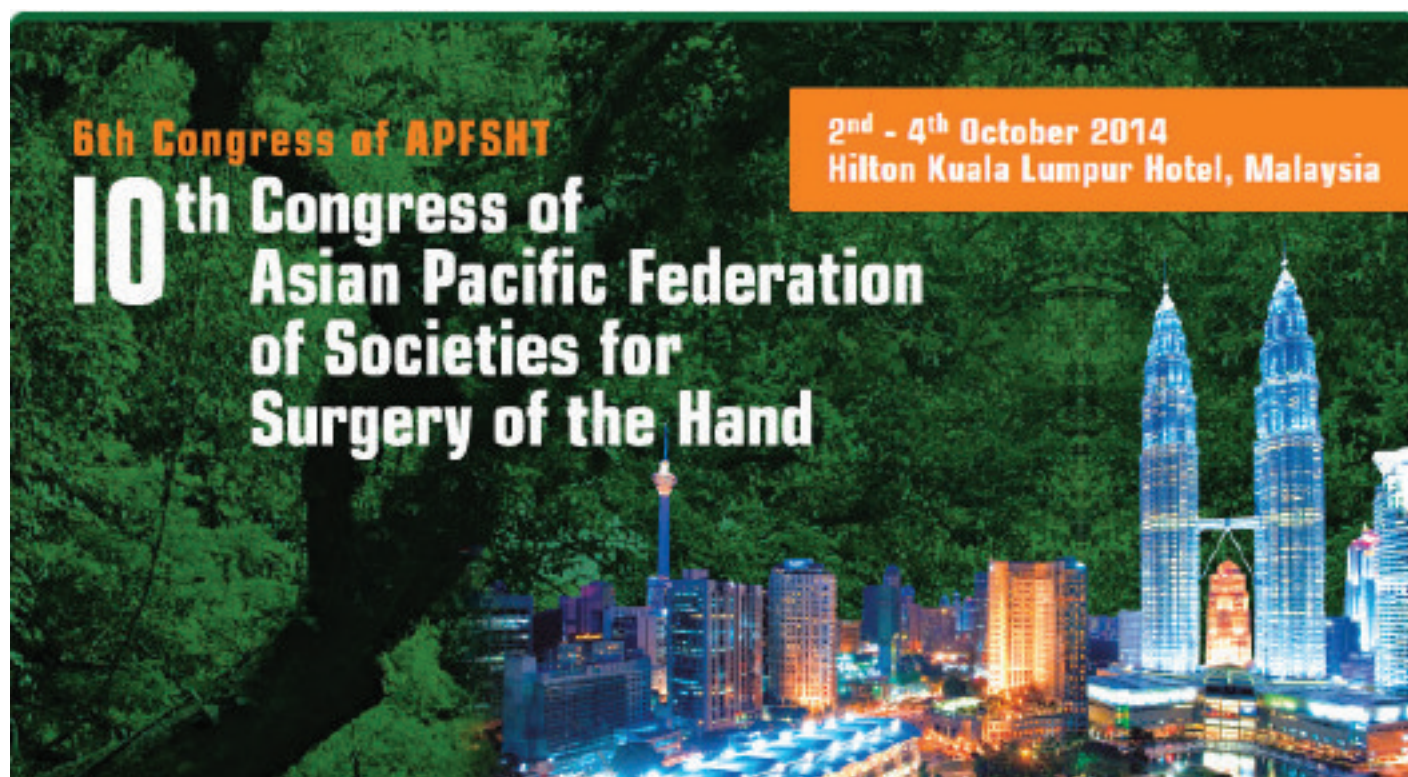
## 10th Congress of the Asian Pacific Federation of Societies for Surgery of the Hand

**2-4 October 2014, Kuala Lumpur, Malaysia**

**[www.apfssh2014.org](http://www.apfssh2014.org)**

The Malaysian Society for Surgery of the Hand (MSSH) is pleased to invite you to the 10th Congress of the Asian Pacific Federation of Societies for Surgery of the Hand (10th APFSSH) and 6th Congress of the Asian Pacific Federation of Societies for Hand Therapists (APFSHT) which will be held from 2nd - 4th October 2014 at Hilton Kuala Lumpur Hotel, Kuala Lumpur, Malaysia. To make it more exciting and well worth your while, ISSPORTH and IBRA are also joining in the academic activities! The conference programme includes:

- Cadaveric Pre-Congress Workshops
- 18 Industry Forms
- Five concurrent sessions with 99 symposia and 12 plenaries
- ISSPORTH - International Society for Sport Traumatology of the Hand Meeting
- Exhibition booth showcase
- Digital interface showcase
- International Bone Research Association (IBRA) meeting



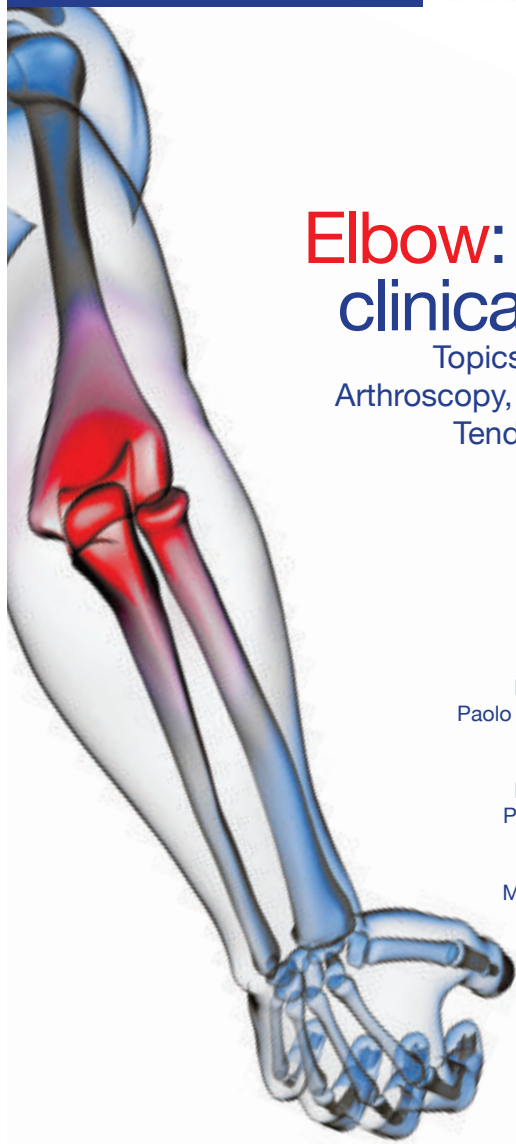
## Elbow: diseases and clinical experiences: hands-on Cad Lab

13-15 November 2014


Arezzo, Italy


[www.sicm.it](http://www.sicm.it)

Topics on Anatomical approaches, Arthroscopy, Arthroplasty and Prosthesis, Tendon repair and reconstruction. President, Bruno Battiston. Scientific Committee: Andrea Atzei, Riccardo Luchetti.



Under the auspices of

 **SICM**  
Società Italiana di Chirurgia della Mano

 **nicola's**  
foundation  
onlus

**PRELIMINARY PROGRAM**  
**Hands-on Cad Lab**

**November 13<sup>th</sup> - 15<sup>th</sup> 2014**

# Elbow: diseases and clinical experiences

Topics on Anatomical approaches,  
Arthroscopy, Arthroplasty and Prosthesis,  
Tendon repair and reconstruction

**President**  
Bruno Battiston

**Scientific Committee**  
Andrea Atzei, Riccardo Luchetti

**Provisional Faculty**

Renzo Angeloni	Maurizio Fontana
Paolo Angelo Arrigoni	Enrico Guerra
Andrea Atzei	Michael Hausman
Mark E. Baratz	Riccardo Luchetti
Bruno Battiston	Italo Pontini
Prospero Bigazzi	Roberto Rotini
Filippo Castoldi	Luigi Tarallo
Andrea Celli	Pierluigi Tos
Massimo Ceruso	Adolfo Vigasio

**CME CREDITS Requested**

**SPECIAL SESSION FOR THERAPISTS**

## One-Day International Shoulder and Elbow Symposium

18 October 2014

London, Euston

[www.welbeing-cpd.co.uk/Page.aspx?P\\_ID=15](http://www.welbeing-cpd.co.uk/Page.aspx?P_ID=15)

The European Society for Shoulder & Elbow Rehabilitation is the only Europe wide society that connects healthcare professionals with an interest in shoulder and elbow dysfunction. The objective of the society is to provide the highest standard of information and education to enhance patient care. This conference is a unique opportunity to hear international expert speakers on the topic of instability in the upper limb. The conference aims to explore both surgical and conservative perspectives on how to manage dysfunction in the shoulder and elbow. Clinical cases will be discussed amongst the faculty to generate debate as well as nuggets of advice. This conference is targeted to surgeons, therapists and physicians.

## 10th World Symposium on Congenital Malformations of the Hand and Upper Limb

7-9 May 2015

Rotterdam, The Netherlands

[worldcongenitalhand2015.com](http://worldcongenitalhand2015.com)

The 10th World Symposium on Congenital Malformations of the Hand and Upper Limb will be held on the 7th-9th May 2015, in Rotterdam,





# 10<sup>th</sup> World Symposium on Congenital Malformations of the Hand and Upper Limb

7-9 May 2015 Rotterdam, The Netherlands

[www.worldcongenitalhand2015.com](http://www.worldcongenitalhand2015.com)

The Netherlands. A broad variation of congenital hand anomalies, genetics, embryology and classification will be presented, discussed and shared. Invited lectures, discussion, free paper sessions and panel sessions will inform you of the latest on congenital hand anomalies. Some of the keynote speakers are Michael Tonkin, Caroline Leclercq and Ann van Heest. The symposium will be preceded by a cerebral palsy pre course on Wednesday the 6th of May. For more information on the program and registration go to: [www.worldcongenitalhand2015.com](http://www.worldcongenitalhand2015.com)

## Surgical techniques in hand surgery: Ligaments, tendons, fractures and arthroplasty

11-13 December 2014

Arezzo, Italy

President, Roberto Adani. Scientific  
Committee:

Massimo Ceruso, Pierluigi Tos

[www.sicm.it](http://www.sicm.it)

Under the auspices of



SICM  
Società Italiana di Chirurgia della Mano



nicola's  
foundation

Special Session for Therapists

PRELIMINARY PROGRAM

**December**  
**11<sup>th</sup> - 13<sup>th</sup>**  
**2014**

**SURGICAL TECHNIQUES  
IN HAND SURGERY:  
Ligaments, Tendons,  
Fractures and Arthroplasty**

**Hands-on Cad Lab**

**President**  
Roberto Adani

**Scientific Committee**  
Massimo Ceruso  
Pierluigi Tos

**Provisional Faculty**

Roberto Adani	Giulio Lauri
Massimo Ceruso	Alberto Lluch
Tyson Cobb	Gianfranco Merendi
David Elliot	Frank Nienstedt
David Espen	Michele Riccio
Nicola Felici	Marco Rizzo
Thomas Giesen	Pierluigi Tos
Riccardo Giunta	Adolfo Vigasio

# NEXT IFSSH & IFSHT

NEW DATES  
**24-26  
October  
2016**

October 09 - 13, 2016

Argentina  
Buenos Aires

**Make your plan for attending  
to the first Congress in South America!**

**Hilton Buenos Aires  
& Convention Center**



**Scientific Program:** Symposia on the most controversial topics, updates by world renowned experts and best selected free papers.

**Special Social Events** and Tango Shows.  
High quality meat and exquisite Malbec Wines.

**High ranked Tourism:** Patagonia and it's glaciers, Iguazú Falls, Mendoza's Wine Routes and the incredible views of Purmamarca (Salta and Jujuy).

**[www.ifssh-ifsht2016.com](http://www.ifssh-ifsht2016.com)**



13th Buenos Aires 2016  
**IFSSH & IFSHT  
Congress**

