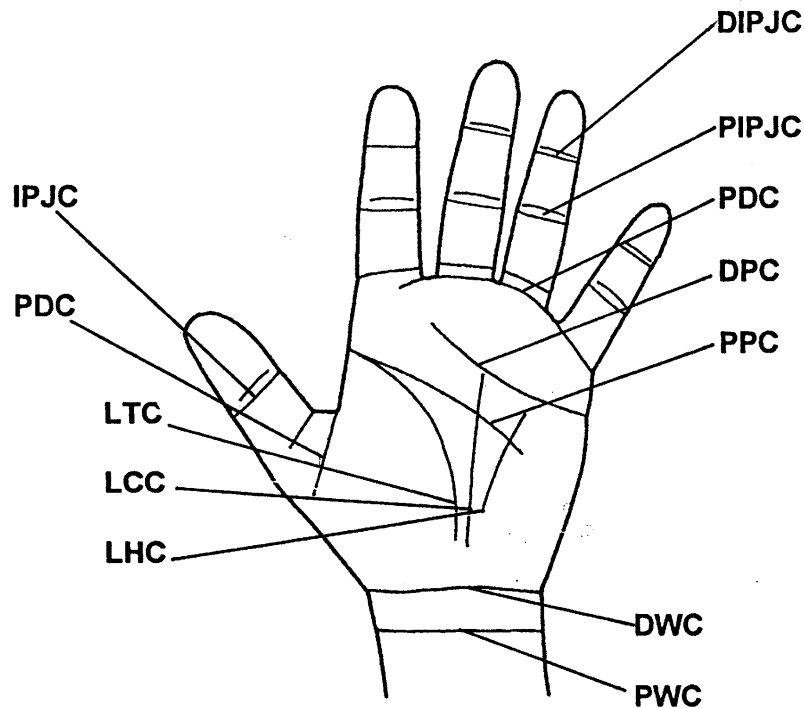


## SKIN CREASES



The skin creases ("joints" of the digital and palmar skin) are listed in the different languages on FASCIA and APONEUROSIS.

**Palmar creases.** In the palm there are three longitudinal and two transverse creases.

The **longitudinal creases** are the thenar, the central and the hypothenar. The most constant and easily differentiated is the thenar crease, due to the wide mobility of the carpo-metacarpal joint of the thumb. The **central and hypothenar** creases are the reflection of the mobility at the carpo-metacarpal joints of the ring and small fingers.

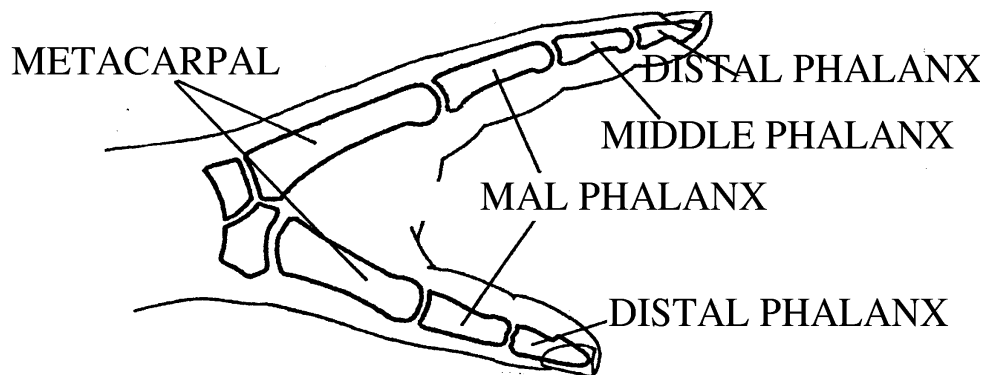
The two **transverse creases** are the proximal and the distal. The distal crease starts at the ulnar side of the hand and finishes in between the middle and index fingers, as most of the hand functions are done with the ulnar fingers in flexion for power grasp, while the index and the thumb remain in extension for precision manipulation. The middle finger can either help the thumb and index for manipulation, or the ring and small fingers if more power grasp is needed. The proximal crease starts at the radial side of the hand along with the longitudinal thenar crease. Flexion of the metacarpo-phalangeal joints takes place in a transverse line between the origin of the distal palmar crease on the ulnar side and the proximal palmar crease on the radial side. Individuals with Down's syndrome just have one transverse palmar crease.

**Digital creases.** Usually there are two creases at the level of each joint, being most proximal the proximal one. The palmar digital crease of the triphalangeal fingers is usually located at the proximal third of the proximal phalanx. The palmar digital crease of the thumb is longitudinally oriented and slightly proximal to the metacarpo-phalangeal joint.

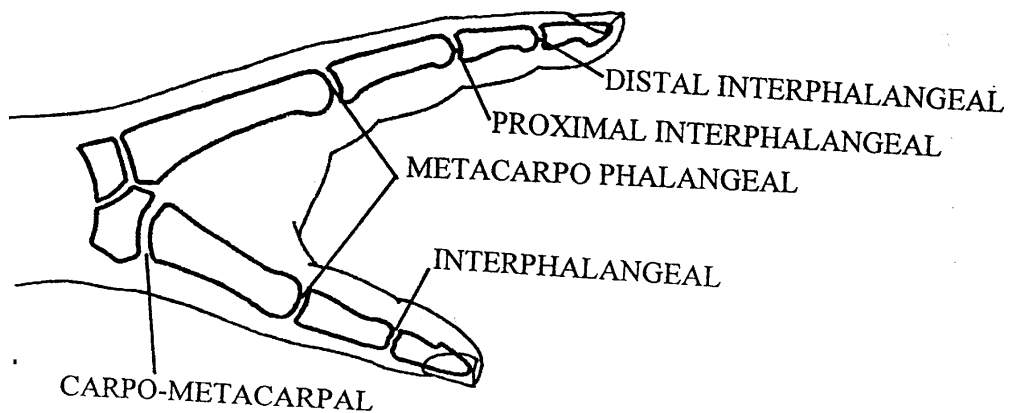
[Top](#)

## THE HAND

In order to avoid mistaken identity, the fingers are referred to by name, rather than the number.



Following the same rule, the **bones** of each finger are named by the name given to that finger. For example: the metacarpal of the index finger or the middle phalanx of the ring finger



The **joints** are named after the name of the bones that they unite. The triphalangeal or long fingers have two interphalangeal joints, which will be named proximal and distal interphalangeal joints. The carpo-metacarpal joints of the thumb is also commonly referred to as trapezio-metacarpal joint.

[Top](#)

## JOINT MOTION

General rules

THE ELBOW

THE FOREARM

THE WRIST

THE FINGERS

THE THUMB

[Top](#)

### General rules

The **anatomical or zero starting position** is considered with the upper extremity aligned next to the trunk with the palm of the hand facing anteriorly. Any joint movement in the anterior direction is considered as flexion and should be recorded as positive degrees. On the contrary, any movement in a posterior direction is called extension, and should be recorded as negative degrees. The extension motion in joints that usually do not extend is called hyperextension.

The terms dorsal flexion or dorsiflexion should be avoided. Dorsal extension is redundant and should not be used.

**Active and passive range of motion** should always be recorded when examining a joint. Passive joint motion can be of greater magnitude in the presence of nerve, muscle or tendon pathology.

In the following pages the most frequently observed arcs of joint movility will be given as an orientation, although they may vary up to 20° in many individuals. It is for this reason that all joint movements should be compared with the normal joint on the opposite extremity.

[Top](#)

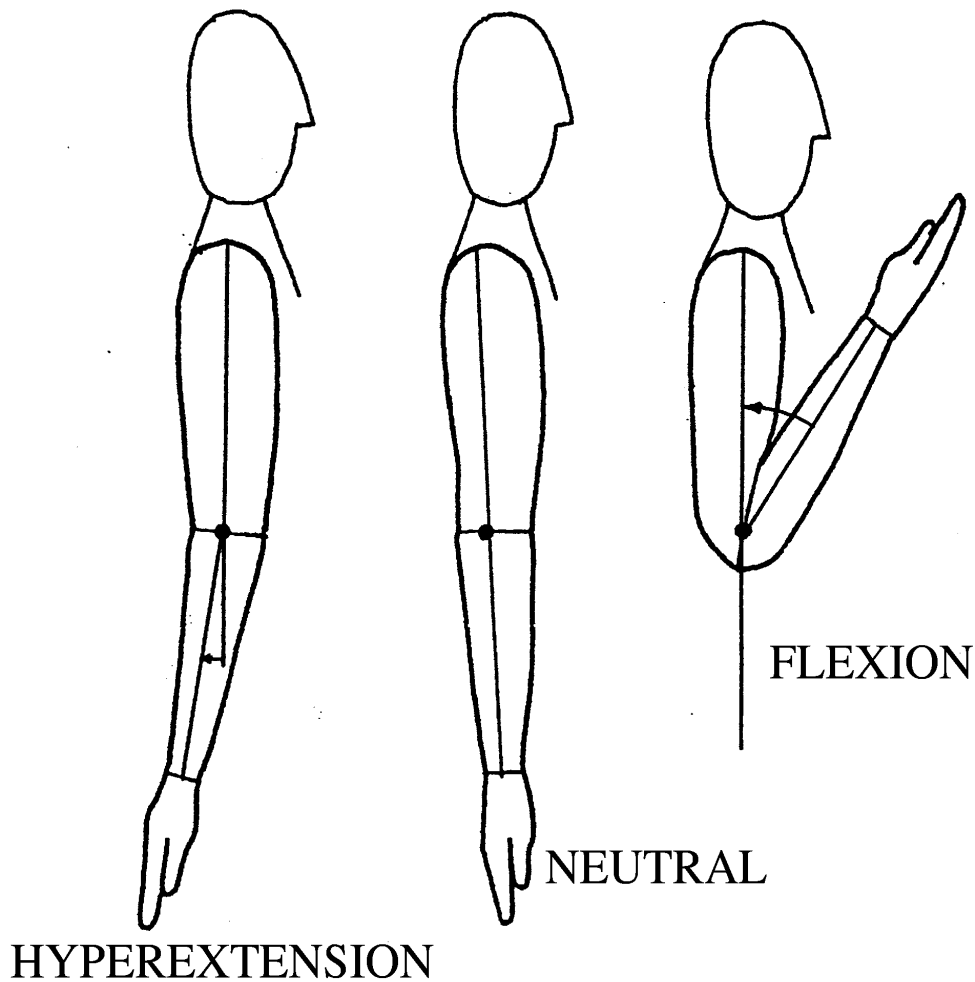
## THE ELBOW

The main joint at the elbow is the humero-ulnar, which is a hinge joint, meaning that only moves in one plane.

The neutral position is in full extension, with the humerus axially aligned with the ulna, and this is considered as the zero starting position.

The elbow flexes to an average of 145°. The only restraints are the soft tissues in the anterior surface of the upper extremity and the bone contact between the coronoid fossa of the humerus and the coronoid process of the ulna. The motion in the direction of flexion is measured as positive degrees from the zero starting position.

Some individuals can slightly hyperextend the elbow. This joint motion is measured as negative degrees.



## THE FOREARM

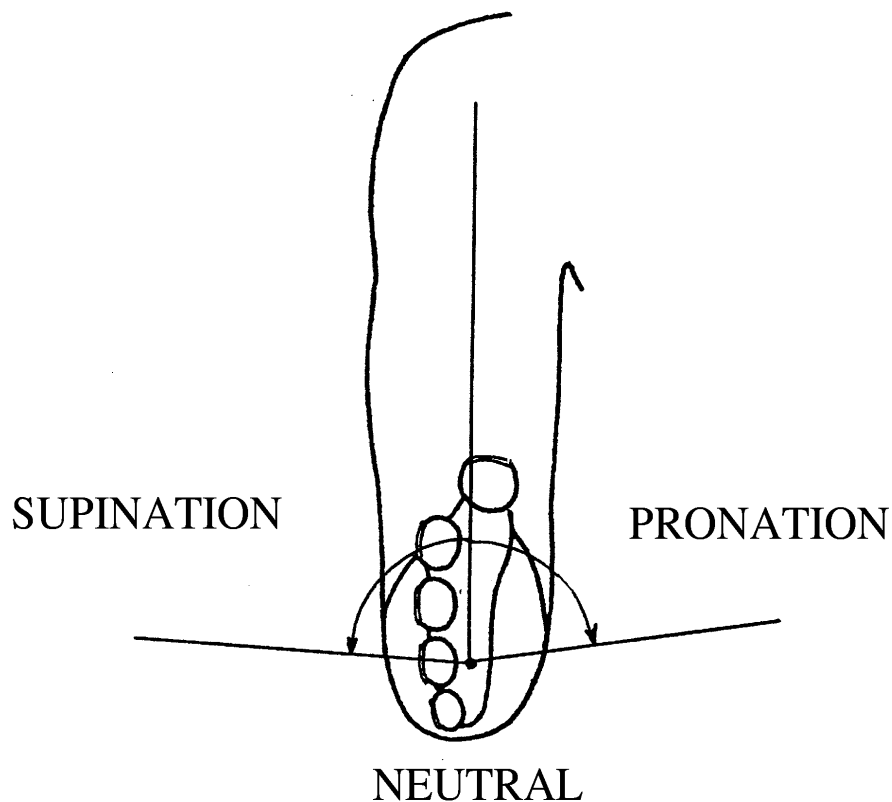
The movements of pronation and supination take place in the forearm. The radius rotates around the ulna along a slightly oblique axis crossing the proximal and distal radio-ulnar joints. The hand is attached to the radius, and follows it during the movements of rotation. The amount of hand supination and pronation at the wrist level is negligible, although a slight degree of passive rotation can be noted.

The scapulo-humeral joint can also internally and externally rotate, transmitting this movement to the hand. This movement of rotation at the shoulder will be blocked if the arm is kept next to the torax and the elbow is flexed 90°.

External rotation is known as supination (the palm of the hand faces the anterior aspect of the arm), and internal rotation is known as pronation (the palm of the hand faces the posterior aspect of the arm), and

Although the zero starting position, or anatomical position of the forearm, is, in fact, full supination, it has been agreed that the neutral position should be considered at the mid point of the full arch of rotation.

The neutral position or zero starting position is with the "thumb up", with the palm of the hand in the sagittal plane. The rotation of the forearm with the palm facing up is known as supination and usually measures 85°. The rotation of the forearm with the palm of the hand facing down is known as pronation, and usually measures 75°, a little less than supination.



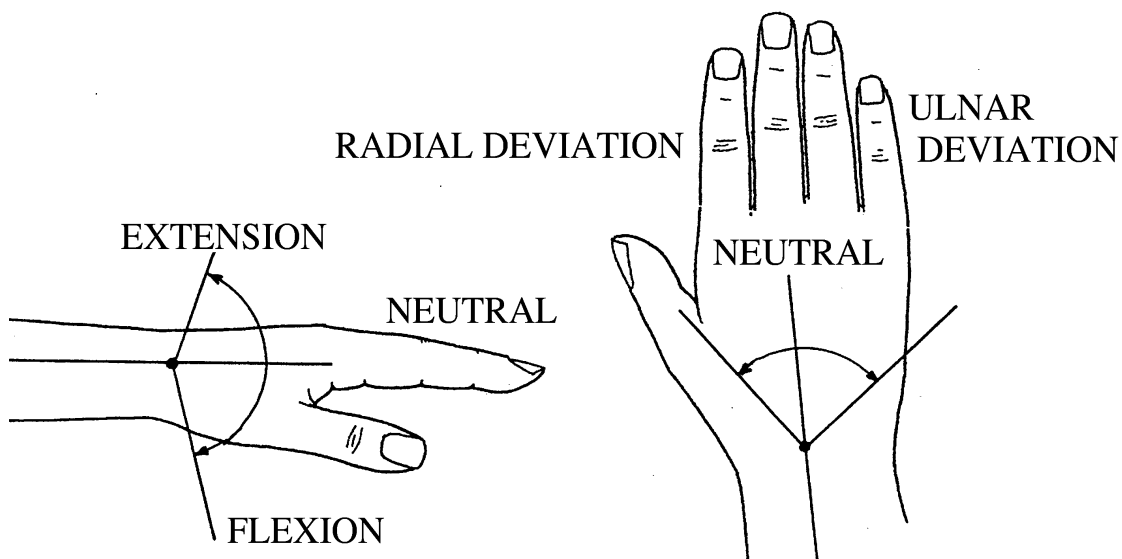
[Top](#)

## THE WRIST

The wrist can move in the sagittal plane (flexion and extension) and in the coronal plane (radial and ulnar deviation). As mentioned before, the wrist allows for some degree of rotation, which can be observed by passive manipulation of the joint. However, this type of movement is almost negligible and cannot be clinically measured.

The neutral or zero starting position is with the longitudinal axis of the middle finger metacarpal aligned with that of the radius.

The wrist usually extends  $70^{\circ}$  and flexes  $80^{\circ}$ . The arc of extension is generally smaller than the one of flexion. Flexion and extension vary among different individuals. Some individuals cannot flex further than  $65^{\circ}$ , while others with joint hyperlaxity can flex the wrist more than  $90^{\circ}$ .



Radial deviation usually measures  $20^{\circ}$ , while ulnar deviation is  $40^{\circ}$ .

Wrist movements are usually measured with the forearm in pronation as this is the position with which the patient presents the hand to the examiner, however, it would be more accurate to perform all wrist measurements with the forearm in neutral position, as there can be minor differences in total range of movement when the forearm is fully pronated.

[Top](#)

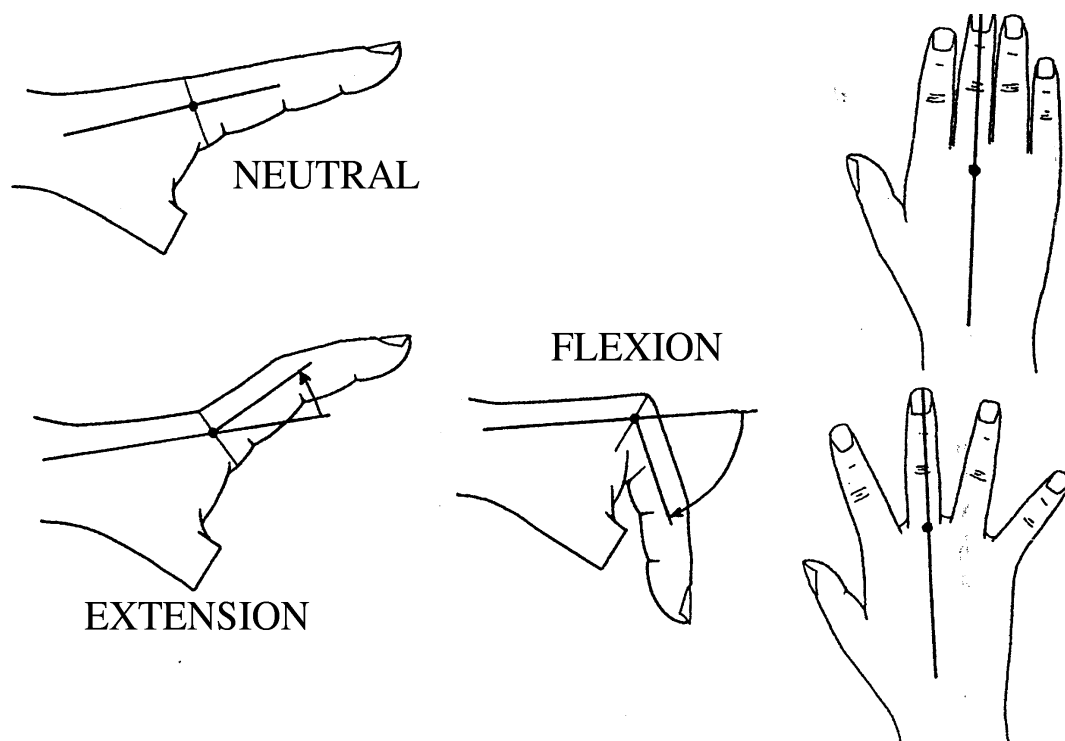
## THE FINGERS

The **METACARPO-PHALANGEAL JOINTS** can move in the sagittal plane (flexion and extension) and in the coronal plane (radial and ulnar deviation). Some degree of rotation is also possible, from selective contraction of the intrinsic muscles. This freedom of movement in pronation and supination is very useful when performing tasks of precision handling. From the practical point of view it is very difficult to measure, and for this reason it is not usually recorded in clinical practice.

The zero starting position is when the proximal phalanx is axially aligned with the metacarpal. The metacarpophalangeal joints flex an average of  $90^\circ$ . The index finger usually flexes less than  $90^\circ$ , but flexion progressively increases in the most ulnar fingers, being more than  $90^\circ$  in the small finger.

The MID joints can hyperextend up to  $30^\circ$ , and even more in individuals with joint hyperlaxity. Full MP joint hyperextension is generally accomplished with moderate interphalangeal joint flexion in order to relax the palmar skin.

The motion of the MP joints in the coronal plane is defined as radial and ulnar deviation. The terms abduction and adduction could also be used, but confusion may arise when defining the longitudinal axis of reference. When using this terminology, the axis of the middle finger ray should be used, rather than the longitudinal axis of the body used for the rest of the joints. This method has the disadvantage of not differentiating the abduction of the middle finger in two opposite directions.

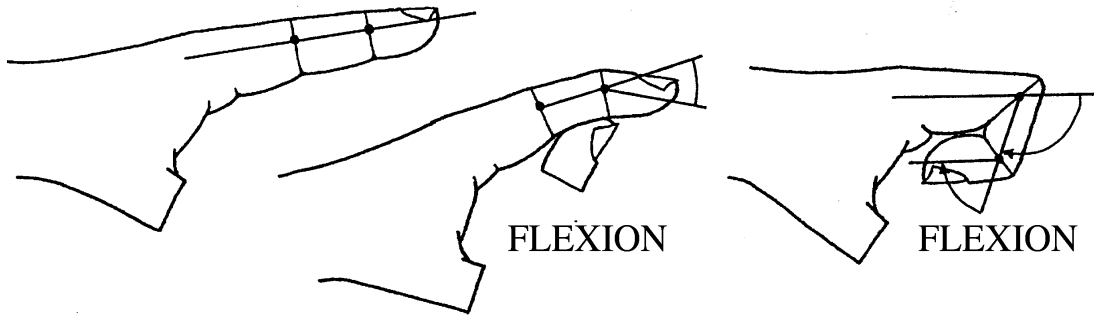


The **INTERPHALANGEAL JOINTS** are hinge joints and can only move in the sagittal plane.

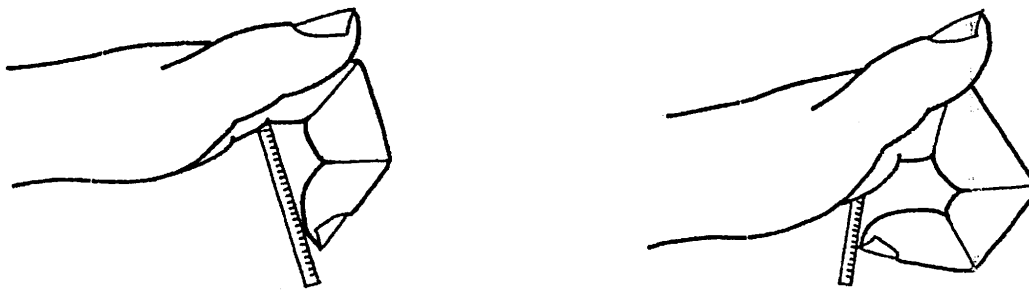
The zero starting position is with the finger in extension, with the three phalanges aligned with each other. Full flexion is accomplished when both proximal and distal phalanx are parallel to

each other, which means a combined flexion of 180°. The PIP joint however flexes a little more than the DIP joint, averaging 105° and 75° respectively.

Some hyperextension of the DIP joint is not unusual; however, hyperextension of the PIP joint is only seen in people with joint laxity.



Motion at the DIP joint should not be measured by holding the PIP joint in extension, as in this position DIP joint flexion will be restricted from preventing the lateral bands to glide to the sides of the PIP joint. Active DIP joint motion should be recorded with all the fingers flexed simultaneously, as the flexor digitorum profundus is a single musculotendon unit, with the occasional exceptions to the index finger.



A quick method of measuring the composite finger motion is by measuring the distance from the fingertip to the palmar-digital crease (this measures flexion of both interphalangeal joints) or to the proximal palmar crease (this also measures the flexion of the MP joint). This method is not fully accurate as different examiners can use different parts of the finger tip as a reference: the free edge of the nail, the end of the fingertip or that part of the finger pulp closer to the skin crease.

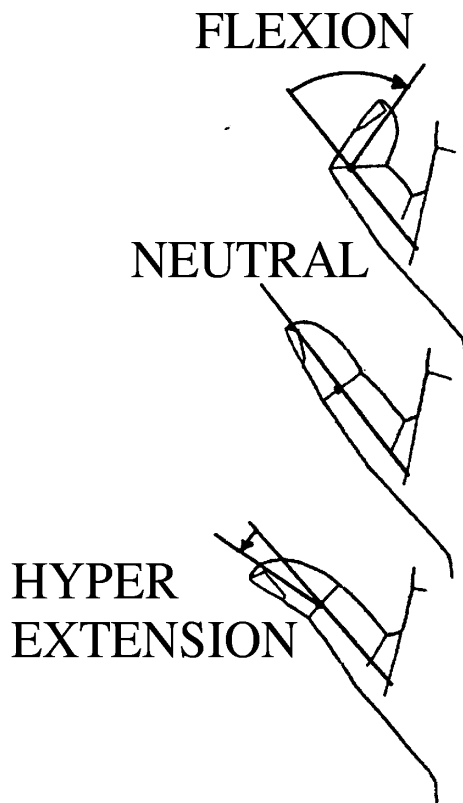
[Top](#)



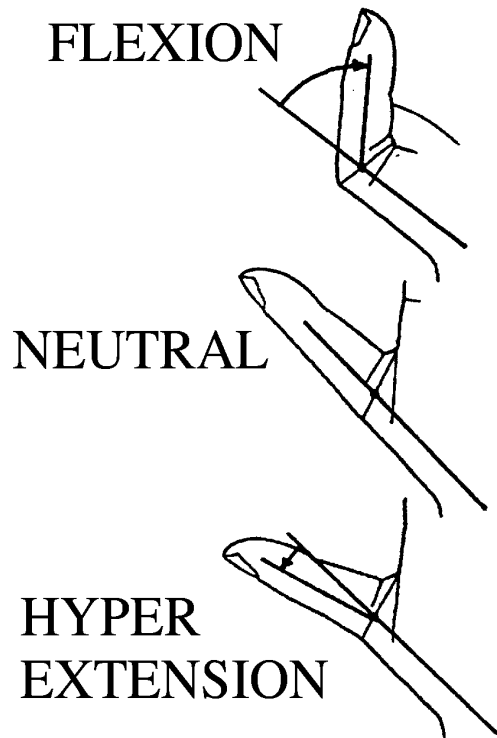
## THE THUMB

The motions of the thumb, mainly at the carpometacarpal joint, are complex, and all definitions are somewhat arbitrary. Motion of the interphalangeal and metacarpo-phalangeal joints take place in a plane perpendicular to the one of the rest of the fingers.

Motion at the **INTERPHALANGEAL JOINT** is limited to flexion and extension, in a plane perpendicular to the nail of the thumb. The zero starting position is with the proximal and distal phalanges aligned to each other. Flexion averages 80°, and many individuals can hyperextend the joint up to 45° or more.




Motion at the **METACARPO-PHALANGEAL JOINT** is mainly in the plane of flexion and extension. Some lateral motion (radial and ulnar deviation) and rotation (supination and pronation) are also present. When the pulp of the thumb is opposed to the pulp of another finger, with the fingernails parallel to each other, some radial deviation and pronation takes place at the MP joint of the thumb. The triphalangeal finger also rotates slightly into supination. There is a wide variation in the range of motion of the MP joint in the different individuals. More than in any other joint of the hand, motion of the MP joint should always be compared to the one in the opposite thumb. Some individuals can only flex the joint about 20°, while others can flex it up to 90°, and even hyperextend it.

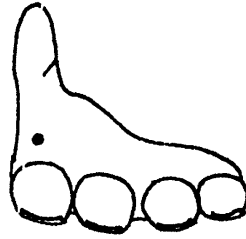
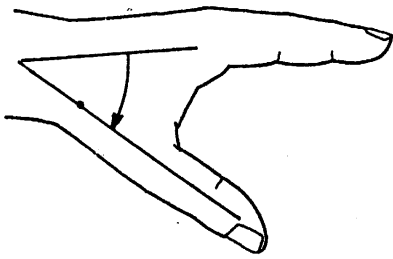


The **CARPO-METACARPAL JOINT (TRAPEZIO-METACARPAL)** is a universal joint, in the sense that it can move in two planes and can also rotate along its longitudinal axis.

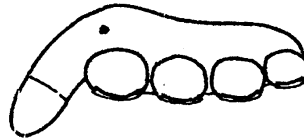

The zero starting position is with the thumb metacarpal as parallel as possible to the index finger metacarpal. The thumb lies next to the antero-radial border of the palm.



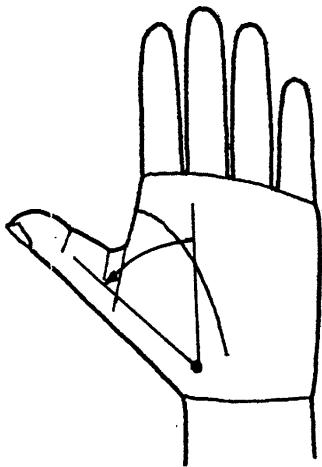
**Anteposition or Palmar abduction** is the movement in which the thumb metacarpal moves away from the index metacarpal at right angle to the plane of the palm. It is measured by the angle formed between the thumb and the index metacarpals, averaging about 40°.



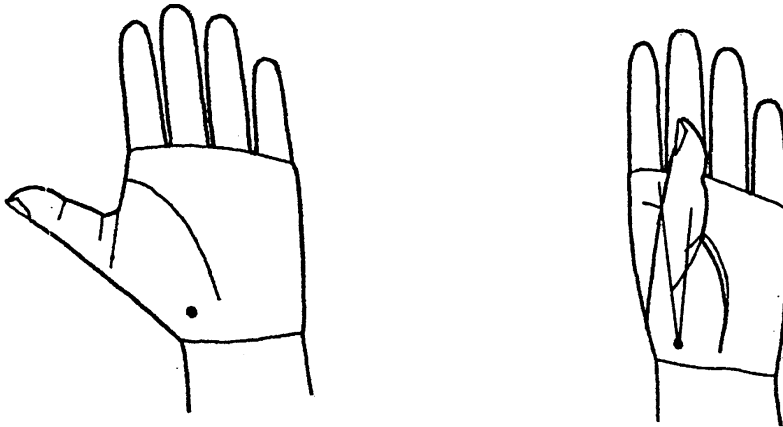
**Retroposition** is the opposite to palmar abduction (ante-position). The thumb moves towards the back of the hand. Retropulsion is measured by the angle formed by the thumb metacarpal passing to the palm, averaging about  $15^{\circ}$ .



**Abduction** or **Radial abduction** (to differentiate it from palmar abduction) is the movement in which the thumb metacarpal moves away from the index finger metacarpal in the plane of the palm. It is measured by the angle formed between the thumb and index metacarpals, averaging about  $40^{\circ}$ .



**Adduction** is the opposite of radial abduction. The thumb metacarpal moves towards the center of the palm. The thumb at the **T-MC** joint is limited to about  $15^{\circ}$

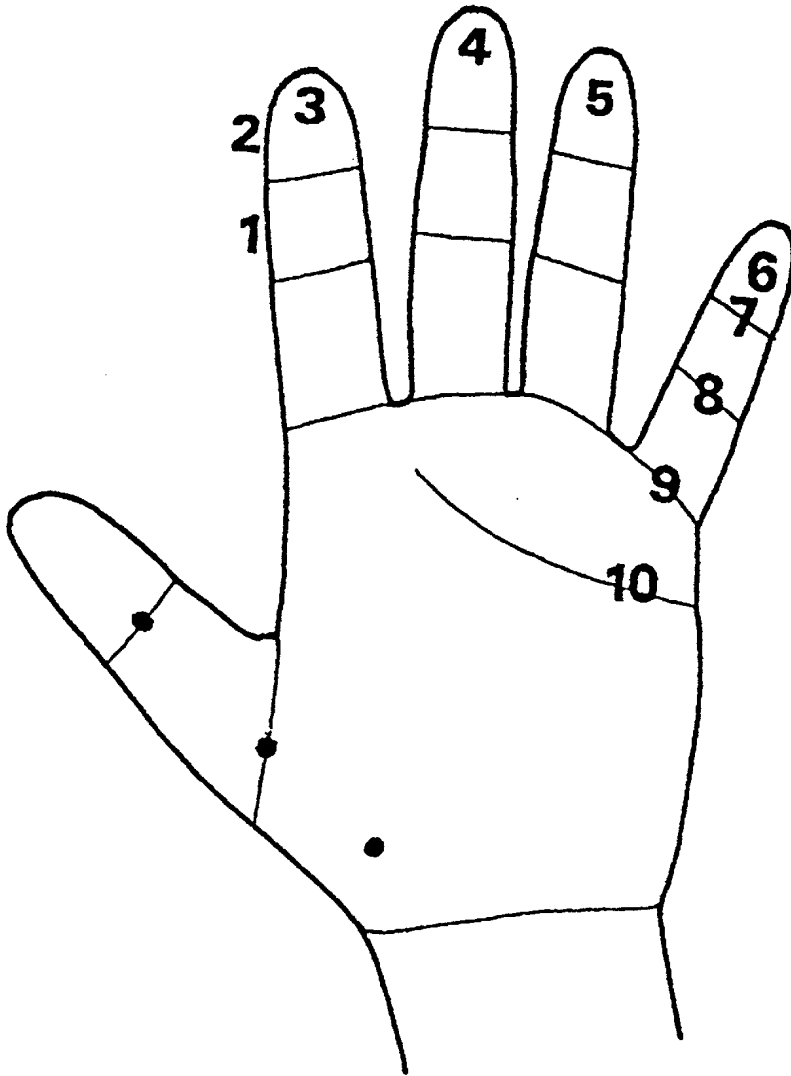


**Opposition** is a composite motion of the entire thumb ray by placing its pulp parallel to that of the rest of the fingers.

Measuring the thumb's opposition is very difficult, because it combines movement at the trapeziometacarpal, metacarpophalangeal and interphalangeal joints. It is the result of different degrees of palmar abduction, pronation (internal rotation), adduction and flexion at the three joint levels.

One way to evaluate this composite motion is by the Total Opposition Test (**TOT**). It is divided into 10 stages, according to the place where the pulp of the thumb reaches the different parts of the fingers. Stages 7 to 10 do not measure true opposition, but rather adduction of the T-MC joint, and flexion of MID and IP joints.

The examiner should be aware that an apparent loss of thumb opposition to the small finger can also be secondary to a loss of opposition of the latter, from hypothenar muscle weakness or C-MC joint stiffness.



[Top](#)