



IFSSH Scientific Committee on Carpal Instability

Part 2: Management of scapho-lunate dissociation

Chair: Max Haerle (Germany)

**Committee: Abhijeet Wahegaonkar (India)
Marc Garcia-Elias (Spain)
Gregory Bain (Australia)
Riccardo Luchetti (Italy)**

Report submitted May 2016

Part 2: Carpal Instability - Management of scapho-lunate dissociation

PRINCIPLES OF MANAGEMENT

Garcia-Elias²⁷ developed a set of 6 questions that provide a useful framework for developing stage-based treatment algorithms:

- 1) Is the dorsal SL ligament intact?
- 2) If repaired, has it good chances of healing?
- 3) Is the radioscapoid angle normal?
- 4) Is the lunate uncovering index normal?
- 5) Is the misalignment easily reducible?
- 6) Are the joint cartilages normal all over the wrist?

By answering these questions in terms of yes or no, each case can be placed into one of seven categories (Table 3). As expected, the increasing number of negative answers indicates a progression of the dysfunction from minimal (Stage 1) to maximal (Stage 7). In general, all instabilities from the same stage will be treated similarly.

Table 3

	Stage 1	Stage 2	Stage 3	Stage 4	Stage 5	Stage 6	Stage 7
Is the dorsal SL ligament intact?	YES	NO	NO	NO	NO	NO	NO
If repaired, has it good chances of healing?	YES	YES	NO	NO	NO	NO	NO
Is the radioscapoid angle normal?	YES	YES	YES	NO	NO	NO	NO
Is the lunate uncovering index normal?	YES	YES	YES	YES	NO	NO	NO
Is the misalignment easily reducible?	YES	YES	YES	YES	YES	NO	NO
Are the joint cartilages normal?	YES	YES	YES	YES	YES	YES	NO

From Garcia-Elias M: Classification of SL instability, In: Shin & Day (eds) "Advances in Scapholunate Ligament Treatment eBook". Chicago: American Society for Surgery of the Hand, 2014

Treatment of Scapholunate Ligament Injury

Treatment of SLD is difficult, not always predictable, and seldom entirely satisfactory. Patient selection is very important when deciding which treatment is most appropriate. The patient's age, occupation, recreational demands, and level of symptoms must all be considered. There are several different treatment options based on the severity of the SL ligament injury (Figure 15). Mildly symptomatic patients can be treated conservatively with wrist splinting and activity modification. Surgical treatment of scapholunate dissociation is dependent on the severity of the instability (i.e. predynamic, dynamic, or static), the chronicity of the injury, and the presence of any degenerative changes to the carpus.

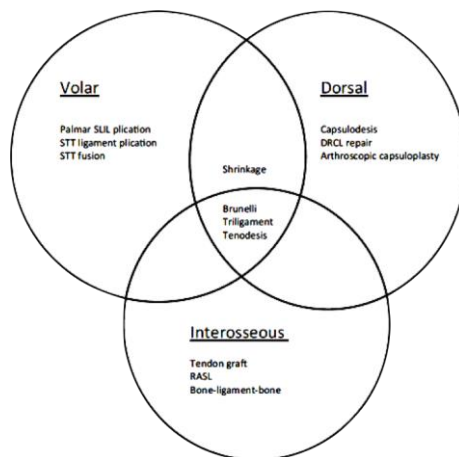


Figure 15 The SL interosseous ligament has 3 parts. The important components are the dorsal and volar aspects. This diagram considers the various treatment options: dorsal, volar or interosseous (which is through the centre of the SL articulation⁴³.

Acute Injuries

In acute injuries, arthroscopy can be used to determine the extent of scapholunate interosseous ligament injury. Partial tears may be treated by percutaneous pinning of the scaphoid and lunate, thus allowing for the possibility of primary healing or fibrosis. Open repair of acute, complete scapholunate interosseous ligament tears, maintains grip strength and wrist motion and presumably halts the progression to degenerative changes and the development of a SLAC wrist.

Predynamic (Occult) Scapholunate Dissociation

Predynamic or occult SL injury results from an incomplete tear of the SL ligament, with a normal radiographic appearance throughout the entire range of motion or under stress. Frequently there is a disruption of the palmar and proximal connections of the SL joint but not the dorsal aspect of the ligament. In the acute phase, when the healing potential of the disrupted ligaments is at its best, a percutaneous or arthroscopically guided Kirschner wire fixation is recommended.²³ In the chronic predynamic instability, three different approaches have been proposed: (1) proprioception re-education of the flexor carpi radialis muscle²⁸⁻³⁰, (2) arthroscopic debridement alone of the torn ligament edges, and (3) electrothermal ligament shrinkage.

Dynamic Scapholunate Dissociation

Dynamic SLDs are characterized by a complete disruption of all SL ligaments (including the dorsal ligament) and by preservation of the secondary scaphoid stabilizers (STT and RSC ligaments). In these cases, carpal malalignment in dynamic SLD only appears under specific loading conditions (e.g., clenched fist, loaded ulnar deviation). Yet, there is substantial kinematic dysfunction with inability to sustain full load in most wrist positions. If the healing potential of the injured ligaments is optimal, without retraction and correct vascularization of the ligament stumps, a direct repair of the dorsal SL ligament is performed using open or arthroscopic techniques.^{20, 31-37} This is supplemented with a percutaneous SL joint fixation (Figure 16). If the dorsal ligament cannot be repaired, one alternative is to re-create the ligament by using either local tissues from adjacent ligaments or by utilizing a bone-ligament-bone autograft. Another alternative is to perform a dorsal capsulodesis, such as that more recently described by Mathoulin³⁷.

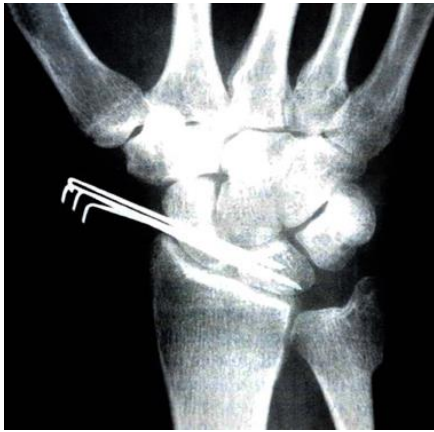

Figure 16 The Whipple technique of arthroscopic assisted stabilisation of the SL interval²³

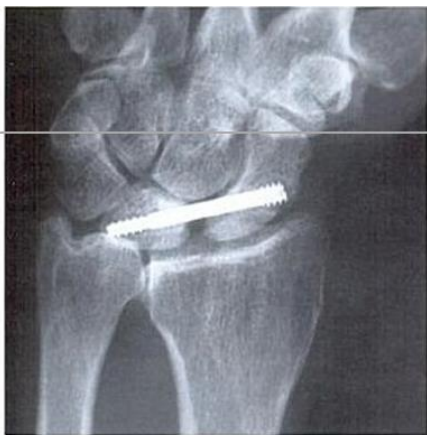

Figure 17 The RASL procedure with the SL interval stabilised with a cannulated screw⁴⁰

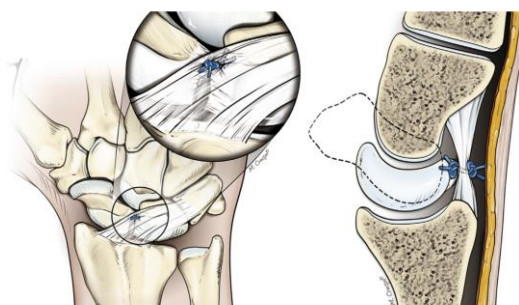


Figure 18 Arthroscopic dorsal capsulodesis, with plication of the dorsal soft tissues adjacent to the SL interval³⁷

Static Reducible Scapholunate Dissociation

An SLD is considered “reducible static” when (1) the ligament rupture has not healed in the acute phase, its remnants having degenerated into a retracted, disorganized fibrous stump, precluding a strong direct repair; (2) the secondary stabilizers (DIC, STT and SC ligaments)^{10, 11, 33} have failed, and a permanent (static) malalignment has appeared; (3) carpal subluxation still is reducible; and (4) no cartilage deterioration has appeared yet. If the ligament has avulsed off the scaphoid or the lunate, ligament repair can still be performed. The repair may be augmented with a dorsal capsulodesis to compensate for the loss of the secondary stabilizers (Figure 18). Unfortunately, these repairs often remain unstable.

For this reason, many different techniques have been developed, in order to stabilize the joint and make the results more predictable. However, many techniques still fail e.g. Bone-Ligament-Bone reconstructions, pure capsulodesis techniques, tendon transpositions^{38, 39} and the so-called RASL procedures (reduction-association of the SL joint) (Figure 17)⁴⁰. Why they fail is still unknown. Some of the studies show low statistical evidence due to low numbers.

On the other hand, several tenodesis techniques have been described in the attempt to reconstruct the forces of the secondary stabilizers²⁷ (Figures 19, 20). Some of the more recent techniques show promise, but need further review^{56, 60, 61, 62}. The results of these operations may be more predictable and may be considered as a valid solution, at this point in time, before proceeding to salvage procedures. Further research, is required to identify the best methods of repair, graft and stabilisation.

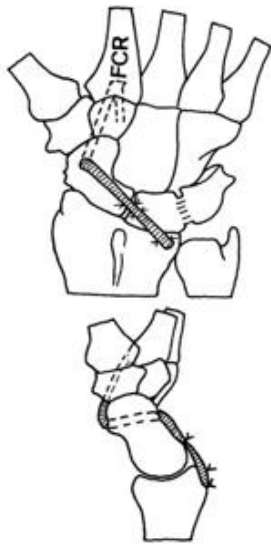


Figure 19 The FCR tendon is passed through the scaphoid and then onto the dorsal radius to stabilises the proximal pole of the scaphoid^{38,59}.

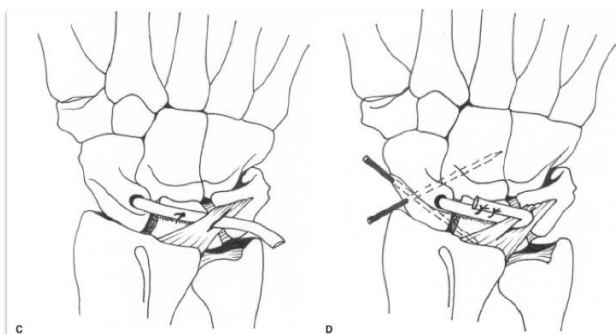


Figure 20 The three-ligament tenodesis for the treatment of scapholunate dissociation²⁷.

Static Irreducible Scapholunate Dissociation (Without Arthrosis)

Chronic rupture or insufficiency of both primary and secondary SL ligament stabilizers results in the formation of fibrosis between the scaphoid and surrounding carpus. With time, subluxated joint surfaces tend to deform, making the carpal malalignment even more irreducible. These cases represent irreducible static SLD. The results of ligament repair and tenodesis are poor in this group, therefore the most frequently recommended treatment for the symptomatic, irreducible carpal malalignment secondary to an SLD is a partial wrist fusion.

Wrist Arthrosis Secondary to SLD (SLAC Wrist)

Long-standing SLDs progressively deteriorate the adjacent joint cartilages following a specific pattern of osteoarthritis, the so-called SLAC wrist. The cartilage wear initiates between the tip of the radial styloid and the distal scaphoid and progresses proximally until the entire RS joint is involved. At a later stage, the midcarpal joint may also degenerate, usually starting at the lunocapitate interval. In advanced cases, the rest of the carpus may be involved, with the exception of the radio-lunate joint, which typically is spared from this degenerative process.⁷

Options for treating SLAC wrist include: 1) Radial styloidectomy, 2) Scaphoid replacement arthroplasty, 3) Three and four corner fusion^{45,46,49}, 4) Proximal row carpectomy⁵³ 5), Wrist denervation⁵², 6) Hemiarthroplasty⁵⁴, 7) Total wrist arthroplasty⁶⁴, and 8) Total wrist arthrodesis⁵⁵.

Radial styloidectomy

Radial styloidectomy is an old procedure designed to relieve pain caused by severe impaction of the tip of the radial styloid against a malpositioned distal scaphoid. When performing a radial styloidectomy, care is required to protect the dorsolateral branches of the superficial radial nerve, and not to detach the origin of the radiocarpal ligaments, as this might lead to further instability.

Scaphoidectomy and midcarpal fusion

Popularized by Watson and co-workers⁷ the SLAC procedure (scaphoid excision plus capitate-lunate-triquetrum-hamate fusion, also known as four-corner fusion) has gained wide reputation for the treatment of chronic SL dissociation. For it to be successful, however, good articular cartilage at the RL level is required. It is important to fully correct the DISI extension malalignment before fusing the midcarpal joint. Low-profile circular or square plates have been designed to avoid dorsal radiolunate impingement, but considerable concerns have been raised due to the high rate of complications and nonunions^{50, 51}. In selected cases, fusion is only recommended to the lunocapitate joint,

particularly in ulnar-plus wrists. Cadaveric studies have suggested that by excising both the scaphoid and triquetrum there will be a better range of motion ^{49, 52}. A subjective and objective functional outcome study has demonstrated a better outcome for the 3 corner fusion than the 4 corner fusion ⁴⁶. The long term results of midcarpal fusion have been generally good, but attention to surgical detail is important^{44, 63}.

Proximal row carpectomy

Proximal row carpectomy is a salvage operation consisting of the complete excision of the proximal row, in order to create a neoarticulation between the capitate and lunate fossa of the radius. Most published series show proximal row carpectomy as an excellent choice, providing an excellent outcome in terms of pain relief ⁵³.

Table 4: Comparison of the outcomes of proximal row carpectomy and four corner fusion⁵⁷

	Proximal row carpectomy	Four-corner fusion
Common indications	SLAC (stage 1 and 2) SNAC (stage 1 and 2) Kienböck (Lichtman IIIB, Bain 2B)	SLAC (all stages) SNAC (all stages) LTAC
Pain relief	84%	85%
Patient satisfaction	80%	90%
Range of motion (of contralateral hand)	60%	50%
Grip strength (of contralateral hand)	70%	75%
Complications		
Development of OA	3.7%	1.4%
CRPS	1%	1%
Sepsis	0.4%	0.6%
Nonunion		5.5%
Dorsal impingement		2.6%
Hardware problems		3.3%
Conversion to total wrist fusion	4%	3%

Abbreviations: 4CF, four-corner fusion; CRPS, chronic regional pain syndrome; LTAC, lunotriquetral advanced collapse; OA, osteoarthritis; PRC, proximal row carpectomy; SLAC, scapholunate advanced collapse; SNAC, scaphoid nonunion advanced collapse.

Total wrist arthroplasty

Total joint replacement of the wrist is a reasonable treatment for patients with low demand on their wrists⁶⁴. Unfortunately, most patients with late post-traumatic instability are young and active individuals, if not heavy duty manual labourers. In such cases, a joint prosthesis may not be an acceptable choice. If the cartilage of the proximal surface of the capitate is preserved, there is the option of replacing only the proximal row by a hemiarthroplasty ⁵⁴.

Total wrist arthrodesis

Arthrodesis still is the procedure of choice in patients involved in heavy manual work. According to some sources, total pain relief can be expected in 85% of patients with 65% of them returning to their former occupations. As shown in many clinical series, most patients with total wrist fusion are able to accomplish all daily tasks by learning to compensate for the loss of wrist motion ⁵⁵.

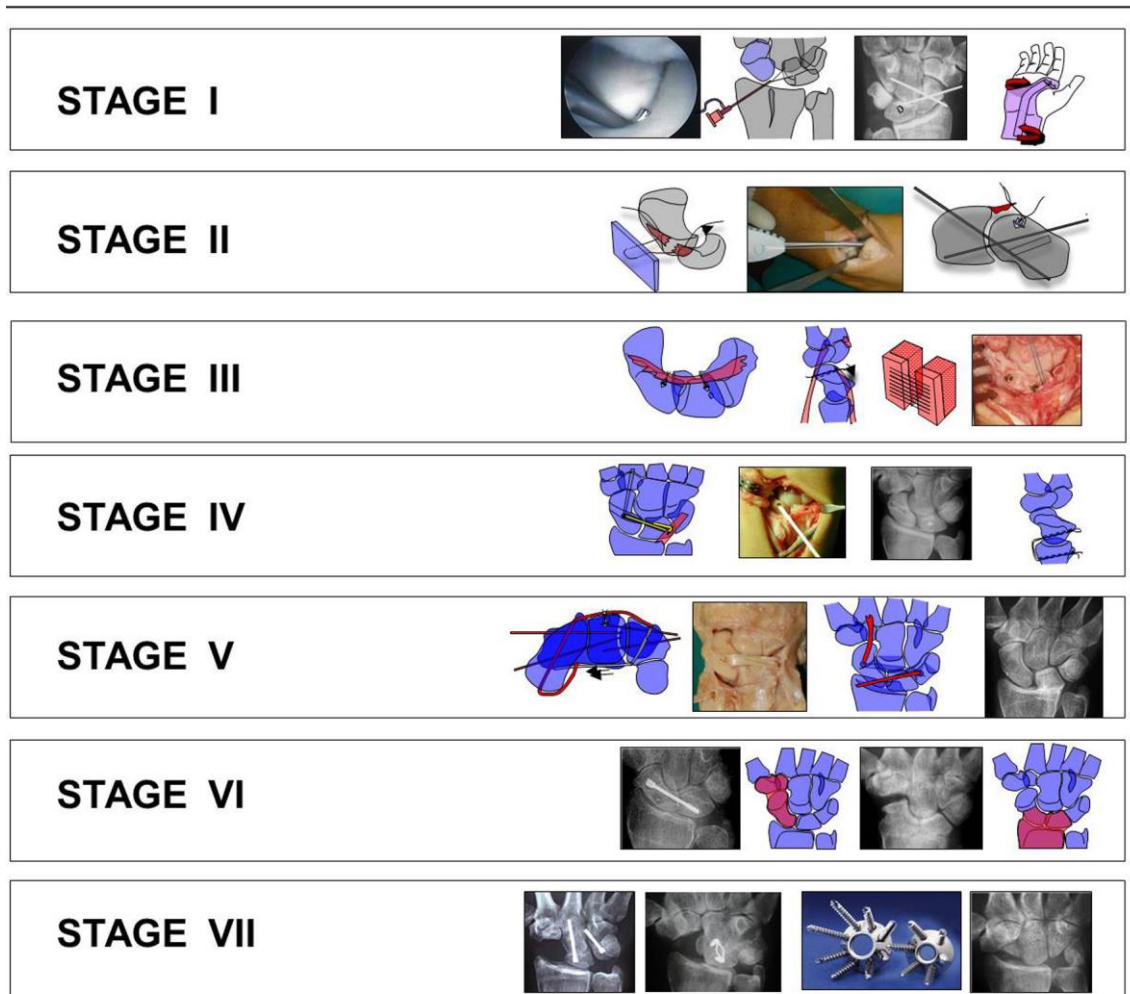


Figure 21 Summary figure demonstrating the various stages, and the associated treatment options.

Denervation has been promoted by some authors ⁵². Various studies have shown the benefit of this procedure especially in an arthritic wrist. Nevertheless proprioception of the wrist begins in sensory end organs located in ligaments and joint capsules (mechanoreceptors). When these mechanoreceptors are stimulated, an afferent signal causes an involuntary spinal reflex that induces a selective muscular contraction in order to protect from ligament injury. The aim of the most recent investigation in this

regard is to provide an understanding of the role of proprioception and neuromuscular control in carpal instabilities, as well as descriptions of potential clinical applications.

It has been postulated that the ligament-muscle reflexes may have a role in protecting a joint from excessive excursion and from excessive loading, which might have a protective effect on the development of posttraumatic OA. We believe that denervation procedures should be avoided in young non-arthritic wrists where the proprioceptive function may play a role. Conscious training of muscles may protect the carpus from further malalignment and subsequently protection of the SL joint is one future direction that needs to be explored.

Conclusion

There have been steady advances in the understanding of the anatomy, biomechanics and imaging of the wrist with scapholunate instability. However there are still significant gaps in our knowledge base for this patient population. What is a greater issue is to be able to understand the best care for the individual patient. We still struggle to determine the natural history and best treatment for each patient who presents to our clinical practice.

References

1. Linscheid RL, Dobyns JH, Beabout JW, Bryan RS. Traumatic instability of the wrist. Diagnosis, classification, and pathomechanics. *The Journal of bone and joint surgery American volume*. 1972 Dec;54(8):1612-32.
2. Taleisnik J. Classification of carpal instability. *Bulletin of the Hospital for Joint Diseases Orthopaedic Institute*. 1984 Fall;44(2):511-31.
3. Cooney WP, Dobyns JH, Linscheid RL. Arthroscopy of the wrist: anatomy and classification of carpal instability. *Arthroscopy : the journal of arthroscopic & related surgery : official publication of the Arthroscopy Association of North America and the International Arthroscopy Association*. 1990;6(2):133-40.
4. Hodge JC, Gilula LA, Larsen CF, Amadio PC. Analysis of carpal instability: II. Clinical applications. *The Journal of hand surgery*. 1995 Sep;20(5):765-76; discussion 77.
5. Larsen CF, Amadio PC, Gilula LA, Hodge JC. Analysis of carpal instability: I. Description of the scheme. *The Journal of hand surgery*. 1995 Sep;20(5):757-64.
6. Cassidy C, Ruby LK. Carpal instability. *Instructional course lectures*. 2003;52:209-20.
7. Watson HK, Weinzweig J, Zeppieri J. The natural progression of scaphoid instability. *Hand clinics*. 1997 Feb;13(1):39-49.
8. Berger RA. The gross and histologic anatomy of the scapholunate interosseous ligament. *The Journal of hand surgery*. 1996 Mar;21(2):170-8.
9. Kitay A, Wolfe SW. Scapholunate instability: current concepts in diagnosis and management. *The Journal of hand surgery*. 2012 Oct;37(10):2175-96.
10. Elsaidi GA, Ruch DS, Kuzma GR, Smith BP. Dorsal wrist ligament insertions stabilize the scapholunate interval: cadaver study. *Clinical orthopaedics and related research*. 2004 Aug(425):152-7.
11. Overstraeten LV, Camus EJ, Wahegaonkar A, Messina J, Tandara AA, Binder AC, et al. Anatomical Description of the Dorsal Capsulo-Scapholunate Septum (DCSS)- Arthroscopic Staging of Scapholunate Instability after DCSS Sectioning. *Journal of wrist surgery*. 2013 May;2(2):149-54.
12. Garcia-Elias M, Ribe M, Rodriguez J, Cots M, Casas J. Influence of joint laxity on scaphoid kinematics. *Journal of hand surgery*. 1995 Jun;20(3):379-82.
13. Galley I, Bain GI, McLean JM. Influence of lunate type on scaphoid kinematics. *The Journal of hand surgery*. 2007 Jul-Aug;32(6):842-7.
14. Haase SC, Berger RA, Shin AY. Association between lunate morphology and carpal collapse patterns in scaphoid nonunions. *The Journal of hand surgery*. 2007 Sep;32(7):1009-12.
15. Bain G, et al. The Effect Of Lunate Morphology on Three-Dimensional Carpal Kinematics *J Hand Surg Am* 2014

16. Watson HK, Ashmead Dt, Makhlof MV. Examination of the scaphoid. *The Journal of hand surgery*. 1988 Sep;13(5):657-60.
17. Theumann N, Favarger N, Schnyder P, Meuli R. Wrist ligament injuries: value of post-arthrography computed tomography. *Skeletal radiology*. 2001 Feb;30(2):88-93.
18. Mahmood A, Fountain J, Vasireddy N, Waseem M. Wrist MRI Arthrogram v Wrist Arthroscopy: What are we Finding? *The open orthopaedics journal*. 2012;6:194-8.
19. Magee T. Comparison of 3-T MRI and arthroscopy of intrinsic wrist ligament and TFCC tears. *AJR American journal of roentgenology*. 2009 Jan;192(1):80-5.
20. Binder AC, Kerfant N, Wahegaonkar AL, Tandara AA, Mathoulin CL. Dorsal wrist capsular tears in association with scapholunate instability: results of an arthroscopic dorsal capsuloplasty. *Journal of wrist surgery*. 2013 May;2(2):160-7.
21. Katschnig I, Prosquill E. [Arthroscopy of the wrist: compared results of MRT and arthrography and outcome in the arthroscopy -- an examination 1998 to 2003]. *Handchirurgie, Mikrochirurgie, plastische Chirurgie : Organ der Deutschsprachigen Arbeitsgemeinschaft fur Handchirurgie : Organ der Deutschsprachigen Arbeitsgemeinschaft fur Mikrochirurgie der Peripheren Nerven und Gefasse* 2006 Apr;38(2):104-8.
22. Kozin SH. The role of arthroscopy in scapholunate instability. *Hand clinics*. 1999 Aug;15(3):435-44, viii.
23. Whipple TL. The role of arthroscopy in the treatment of scapholunate instability. *Hand clinics*. 1995 Feb;11(1):37-40.
24. Bain GI, Munt J, Turner PC. New advances in wrist arthroscopy. *Arthroscopy : the journal of arthroscopic & related surgery : official publication of the Arthroscopy Association of North America and the International Arthroscopy Association*. 2008 Mar;24(3):355-67.
25. Geissler WB, Freeland AE, Savoie FH, McIntyre LW, Whipple TL. Intracarpal soft-tissue lesions associated with an intra-articular fracture of the distal end of the radius. *The Journal of bone and joint surgery American volume*. 1996 Mar;78(3):357-65.
26. Messina JC, Van Overstraeten L, Luchetti R, Fairplay T, Mathoulin CL. The EWAS Classification of Scapholunate Tears: An Anatomical Arthroscopic Study. *Journal of wrist surgery*. 2013 May;2(2):105-9.
27. Garcia-Elias M, Lluch AL, Stanley JK. Three-ligament tenodesis for the treatment of scapholunate dissociation: indications and surgical technique. *The Journal of hand surgery*. 2006 Jan;31(1):125-34.
28. Hagert E, Garcia-Elias M, Forsgren S, Ljung BO. Immunohistochemical analysis of wrist ligament innervation in relation to their structural composition. *The Journal of hand surgery*. 2007 Jan;32(1):30-6.
29. Salva-Coll G, Garcia-Elias M, Hagert E. Scapholunate instability: proprioception and neuromuscular control. *Journal of wrist surgery*. 2013 May;2(2):136-40.

30. Salva-Coll G, Garcia-Elias M, Llusa-Perez M, Rodriguez-Baeza A. The role of the flexor carpi radialis muscle in scapholunate instability. *The Journal of hand surgery*. 2011 Jan;36(1):31-6.
31. Melone CP, Jr., Polatsch DB, Flink G, Horak B, Beldner S. Scapholunate interosseous ligament disruption in professional basketball players: treatment by direct repair and dorsal ligamentoplasty. *Hand clinics*. 2012 Aug;28(3):253-60, vii.
32. Stuffmann ES, McAdams TR, Shah RP, Yao J. Arthroscopic repair of the scapholunate interosseous ligament. *Techniques in hand & upper extremity surgery*. 2010 Dec;14(4):204-8.
33. Short WH, Werner FW, Sutton LG. Dynamic biomechanical evaluation of the dorsal intercarpal ligament repair for scapholunate instability. *The Journal of hand surgery*. 2009 Apr;34(4):652-9.
34. Szabo RM. Scapholunate ligament repair with capsulodesis reinforcement. *The Journal of hand surgery*. 2008 Nov;33(9):1645-54.
35. Bleuler P, Shafiqhi M, Donati OF, Gurunluoglu R, Constantinescu MA. Dynamic repair of scapholunate dissociation with dorsal extensor carpi radialis longus tenodesis. *The Journal of hand surgery*. 2008 Feb;33(2):281-4.
36. Wahegaonkar AL, Mathoulin CL. Arthroscopic dorsal capsulo-ligamentous repair in the treatment of chronic scapho-lunate ligament tears. *Journal of wrist surgery*. 2013 May;2(2):141-8.
37. Mathoulin CL, Dauphin N, Wahegaonkar AL. Arthroscopic dorsal capsuloligamentous repair in chronic scapholunate ligament tears. *Hand clinics*. 2011 Nov;27(4):563-72, xi.
38. Brunelli F, Spalvieri C, Bremner-Smith A, Papalia I, Pivato G. [Dynamic correction of static scapholunate instability using an active tendon transfer of extensor brevis carpi radialis: preliminary report]. *Chirurgia de la main*. 2004 Oct;23(5):249-53.
39. Surdziel P, Romanowski L, Czarnecki P, Kaczmarek L, Splawski R. Dynamic correction of scapholunate instability using ECRB tendon transfer. *Ortopedia, traumatologia, rehabilitacja*. 2006 Apr 28;8(2):134-8.
40. Rosenwasser MP, Miyasajsa KC, Strauch RJ. The RASL procedure: reduction and association of the scaphoid and lunate using the Herbert screw. *Techniques in hand & upper extremity surgery*. 1997 Dec;1(4):263-72.
41. Viegas SF, Wagner K, Patterson R, Peterson P. Medial (hamate) facet of the lunate. *J Hand Surg Am*. Elsevier; 1990;15(4):564-71.
42. McLean J, Turner, P.C., Bain GI, Rezaian N, Field J, Fogg Q. An association between lunate morphology and scaphoid-trapezium-trapezoid arthritis. *J Hand Surg Eur Vol*. 2009 Dec;34(6):778-82.
43. Nakamura K, Patterson RM, Moritomo H, Viegas SF. Type I versus type II lunates: Ligament anatomy and presence of arthrosis. *J Hand Surg Am*. 2001 May;26(3):428-36.

44. Bain GI, Watt AC. The outcome of scaphoid excision and four corner arthrodesis for advanced carpal collapse at a minimum of ten years. *Journal of Hand Surgery (American)*, 2010, 35A:719-725.
45. Van Riet RP, Bain GI. Three corner wrist fusion using memory staples. *Techniques in Hand and Upper Extremity Surgery*. 10(4):259-262, 2006.
46. Singh HP, Dias JJ, Phadnis J, Bain GI. Comparison of the Clinical and Functional Outcomes Following 3- and 4- Corner Fusions. *JHS (Am)* (40), 6, 1117-1123. 2015.
47. Fogg Q. Scaphoid Variation and an Anatomical Basis for Variable Carpal Mechanics. PhD Thesis. Department of Anatomy, University of Adelaide. 2000-2003.
48. Watts AC, McLean JM, Fogg Q, Bain GI. Scaphoid Anatomy In: The Scaphoid. Editor Slutsky DJ and Slade JF III. New York: Thieme, 2011:3-10.
49. Bain GI, Sood A, Yeo CJ. RSL Fusion with Excision of Distal Scaphoid and Triquetrum: A Cadaveric Study. *JWS* 2014; 03(01): 037-041, doi: 10.1055/s-0033-1364095.
50. Vance MC, Hernandez JD, Didonna ML, Stern PJ. Complications and outcome of four-corner arthrodesis: Circular plate fixation versus traditional techniques. *J Hand Surg AM* 2005;30:1122-7.
51. Trail IA, Murali R, Stanley JK, Hayton MJ, Talwalkar S, Sreekumar R, Birch A. The long-term outcome of four-corner fusion. *Journal of Wrist Surgery*. 2015;4(2):128-133.
52. Wilhelm A. Partial joint denervation: wrist, shoulder and elbow. *Plast Reconstr Surg*. 2010; Jul; 126(1):345-7.
53. Chim H, Moran S. Long-Term Outcomes of Proximal Row Carpectomy: A Systematic Review of the Literature. *J Wrist Surg*. 2012 Nov; 1(2):141-148.
54. Boyer JS, Adams BD. Distal radius hemiarthroplasty combined with proximal row carpectomy: case report. *Iowa Orthop J*. 2010, 30:168-173.
55. Hastings H, Weiss AP, Quenzer D, Wiedeman GP, Hanington KR, Strickland JW. Arthrodesis of the wrist for post-traumatic disorders. *J Bone J Surg AM*. 1996; 78:897-902.
56. Ross M, Loveridge J, Cutbush K, Couzens G. Scapholunate Ligament Reconstruction. *J Wrist Surg*. 2013 May; 2(2):110-115.
57. Bain GI, McGuire DT. Decision Making for Partial Carpal Fusions. *Journal of Wrist Surgery*. 2012;01(02):103-114
58. Herzberg G, Comtet JJ, Linscheid RL, Amadio PC, Conney WP, Stadler J. Perilunate dislocations and fracture-dislocations: a multicenter study. *J Hand Surg AM* 1993;18(5):768-779.
59. Brunelli GA, Brunelli GR. A new surgical technique for carpal instability with scapholunate dissociation. *Surg Technol Int*. 1996;5:370-374.
60. Bain GI, Watts AC, McLean J, Lee YC, Eng K. Cable-augmented, Quad Liagment

Tenodesis Scapholunate Reconstruction. J Wrist Surgery. 2015:

61. Chee KG, Chin AYH, Chew EM, Garcia-Elias M. Antipronation spiral tenodesis - a surgical technique for the treatment of perilunate instability. *The Journal of Hand Surgery*. 2012;Volume 37, p 2611-18.
62. Lee SK, Zlotolow DA, Sapienza A, Karia R, Yeo J. Biomechanical comparison of 3 methods of scapholunate ligament reconstruction. *The Journal of Hand*, 2014;(39) p643-650.
63. Cha SM, Shin HD, Kim KC. Clinical and radiological outcomes of scaphoidectomy and 4-corner fusion in scapholunate advanced collapse at 5 and 10 years. *Ann Plast Surg*. 2013 Aug;71(2):166-9.
64. Krukhaug Y, Lie SA, Havelin LI, Furness O, Hove LM. Results of 189 wrist replacement. A report from the Norwegian Arthroplasty Register. *Acta Orthop*. 2011; Aug;82(4):405-9. doi:10.3109/17453674.2011.588858. Epub.2011.