



IFSSH Scientific Committee on Microsurgery

Chair: Alexandru Georgescu (Romania)

**Committee: Michel Saint-Cyr (USA)
Joon Pio Hong (South Korea)
Pierluigi Tos (Italy)
Ferit Demirkan (Turkey)**

Report submitted March 2014

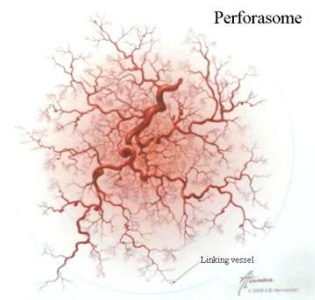Propeller Perforator Flaps in Forearm and Hand Reconstruction

Historical Perspective

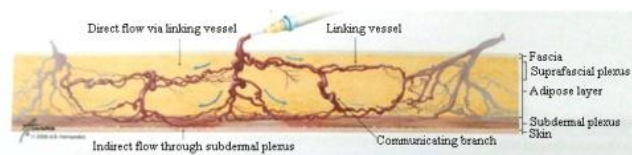
Various methods have been used over the time for reconstruction of challenging tissue defects of the upper limb. But, if for the arm and proximal half of the forearm, the use of a free split thickness graft (FSTG) is generally adequate, the problem becomes more difficult for coverage of tissue defects in the distal forearm and hand. The superficial positioning of important anatomical structures (i.e. tendons, vessels, nerves, bones) in these regions imposes in the large majority of cases the use of local, regional, pedicled or free flaps. A good reconstructive procedure should achieve both cosmetic and functional results and should be customized for a specific defect.

After a long evolution in flap surgery, which included random pattern flaps, muscle and musculocutaneous flaps, fasciocutaneous flaps, Taylor and Palmer[1] reappraised the works of Manchot [2] and Salmon [3] regarding skin blood supply. They developed the angiosome concept, showing that this represents a block of tissue supplied by a same source artery and vein through branches for all tissues between skin and bone. At the same time, neighbouring angiosomes are linked to each other via “choke vessels”.

A step forward was represented by the work of Saint-Cyr et al [4], which focused on the perforator vessels and not the source vessel anymore. After conducting several anatomical studies, they defined the “perforasome” as the vascular territory of a single perforator (Fig. 1 - right), and enunciated four clinically relevant principles:



1. The perforasomes are interconnected by direct and indirect linking vessels (Fig. 2). The direct linking vessels are macroscopic vessels establishing a direct “bridge” between branches of adjacent perforators. The indirect linking vessels are the equivalent of the “choke vessels” described by Taylor and Palmer [1], and constitute the microscopic subdermal network.



*Figure 2:
Direct and indirect linking vessels*

2. The orientation of linking vessels dictates the design of a flap: axial in the extremities (Fig. 3), and perpendicular to the midline in the trunk.

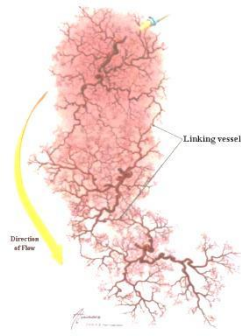


Figure 3: Direction of flow via linking vessels

3. Perforators from a specific source have perforasomes that will be preferentially filled before filling perforasomes from adjacent source vessels
4. The location of a perforator is critical for the inter-perforasome blood flow: the blood flow in linking vessels is distal from joints or non-mobile skin, but when a perforator is relatively centrally located in between two joints, the flow is multi-directional.

Moreover, Rubino et al [5] have shown that by harvesting a flap based on a single perforator, the perfusion in this perforator will increase and contribute to the recruitment of adjacent perforasome territories. That can explain the large dimensions of some flaps.

As a result of this evolution, and following the harvesting of the first flaps sparing the source artery and underlying muscle performed by Kroll and Rosenfield in 1988 [6] and Koshima and Soeda in 1989 [7], the use of perforator flaps became increasingly more extensive. Free perforator flaps such as the anterolateral thigh flap, thoracodorsal artery perforator flaps, lateral arm perforator flap, inferior epigastric artery perforator flap, biceps femoris perforator flap are used successfully for reconstruction of tissue defects in the upper limb.

The distant donor site, the difficulties in obtaining a similar reconstruction, and the technical high-demand procedure are some of the factors that stimulated surgeons to find alternatives to free flaps. In recent years, the use of local perforator flaps gained a big popularity, mainly due to some advantages: (1) replacing like with like, (2) donor site in the same area, (3) possibility of complete or partial donor site primary closure, (4) less demanding from technical point of view, because they do not need microvascular sutures (microsurgical non-microvascular flaps), and (5) shorter operating time [8-11].

Chang et al [12] described for the first time in 1988 a fasciocutaneous forearm reverse flap by sparing the radial artery (RA), but the real interest in using local perforator flaps only became manifest from 1994. Starting with this moment, the use of local perforator flaps in forearm and hand reconstruction became increasingly extensive. Even if these flaps can be used as pedicled and transposition flaps, their use as propeller flaps seems to be more useful and is preferred by most surgeons.

Hyakusoku et al [13] introduced in 1991 for the first time the term, propeller flap, to describe an adipocutaneous flap with blood supply through a random subcutaneous pedicle and rotated through 90 degrees. Later on, Hallock [14] used this term for the first time to define a perforator flap rotated through 180 degrees. The Advisory Panel of the First Tokyo Meeting on Perforator and Propeller Flaps established in 2009 the definition and terminology of propeller perforator flaps: a skin island with two paddles demarcated by the perforator vessel, which has to rotate through at least 90 to 180 degrees [15].

Besides the advantages described above, there are also some possible drawbacks in using these flaps. The most important complications are represented by complete or partial flap loss due to venous problems, but the general complication rate is similar to that for free flaps. In an attempt to minimize the complication rate, the venous supercharging of a flap may be necessary. Of great importance is also the very thoughtful planning and design of the flap, as well as the length of the perforator. One of the most important factors in diminishing the complication rate is the necessity to establish the realistic dimensions of such a flap, in other words the safe vascular limits of a perforator pedicle. While at the beginning it was considered that the dimensions of a perforator flap should not exceed the distance between two perforators, Saint-Cyr et al [4] demonstrated that the single perforator of a flap is hyperperfused, which increases its filling pressure and opens the linking vessels with adjacent territories. It is easy to understand that the possibility of establishing before or during surgery the safer dimensions of a flap can dramatically ameliorate the success rate. A lot of methods were used for this purpose, such as handheld Doppler, color Doppler, Duplex ultrasound, arteriography, magnetic resonance angiography, and high-resolution computed tomography. No single method provides information regarding flap viability, but only about the perforator's distribution and/or calibre [11]. The flap perfusion, but not the dimensions of a flap, can be tested during surgery by fluorescein [11, 16, 17] or indocyanine green near-infrared angiography [11, 18-20].

Due to the superficial location of the main axial source vessels in the distal forearm and hand, the identification of perforator vessels by Doppler examination before surgery is not very useful, because of possible false positive or negative results [9, 10]. In these conditions, it seems more reasonable to find the perforators during surgery by careful microsurgical dissection, and only after that to design the flap: that means to perform a free-style propeller perforator flap.

Propeller Perforator Flaps in the Forearm and Hand

The methods used in the reconstruction of substance loss in the forearm and hand aim to transfer structurally and functionally similar tissues with the price of a low or absent donor site morbidity. It is more than evident that the better way to replace like with like is through the use of local or regional flaps.

Anatomical considerations

The main axial arteries of the forearm, i.e. RA, ulnar artery (UA), posterior interosseous artery (PIOA), and anterior interosseous artery (AIOA), contribute to the perfusion of specific areas of the skin, and constitute a rich anastomotic network with perforator branches providing blood supply to the skin, as well as the muscles. In the forearm, the main vessels follow the axis of the limb, and their perforators connect to each other by means of direct and indirect linking vessels [4]. Between the main arteries there are also some transverse connections, which allow harvesting flaps with pedicles based proximally or distally on the perforators of those arteries [21].

The hand has also a very rich vascularization, based on perforators from the vascular arches realized mainly between the dorsal carpal arch (DCA) and the palmar arterial system [22, 23], but also on perforators of the common digital arteries (CDA) and proper digital arteries (PDA) [24].

Radial Artery

The RA vascularizes the skin between the projection of the palmaris longus and the projection of the lateral edge of the extensor digitorum communis, excepting a small area over the lower part of the extensor pollicis brevis and abductor pollicis longus, which is supplied by the AIOA [25]. The territory of the RA extends proximally up to 5-8cm distal to the epicondylar line of the elbow, but when the inferior cubital artery is present its territory can extend more proximally.

As demonstrated by Saint-Cyr et al, the main perforators of the RA are distributed in two clusters of clinical relevance [26]. The first one is located in the proximal third of the forearm, whereas the second one can be found in the distal fifth of the forearm (Fig. 4). These perforators arise between brachioradialis and pronator teres in the proximal third of the forearm and between brachioradialis and flexor carpi radialis in the distal two thirds of the forearm. In the proximal part the perforators are both muscular and septocutaneous, but in the distal part they are only septocutaneous. One of the septocutaneous perforators in the proximal part is represented by the inferior cubital artery described by Lamberty and Cormack, which is the largest RA perforator and which allows the harvesting of a flap extending 10cm distally from the apex of the antecubital fossa. Two large perforators can be also found within 2cm proximal to the radial styloid (Fig. 5). Other numerous but smaller perforators can be found between 2 and 7cm above the radial styloid (external diameter of 0.3-0.5mm). Moreover, one of the dorsal perforators given by the RA in the distal part, and which is running under or over the brachioradialis tendon and penetrating through it and the abductor pollicis longus tendon, represents the vascular pedicle of a flap described by Koshima et al [27].

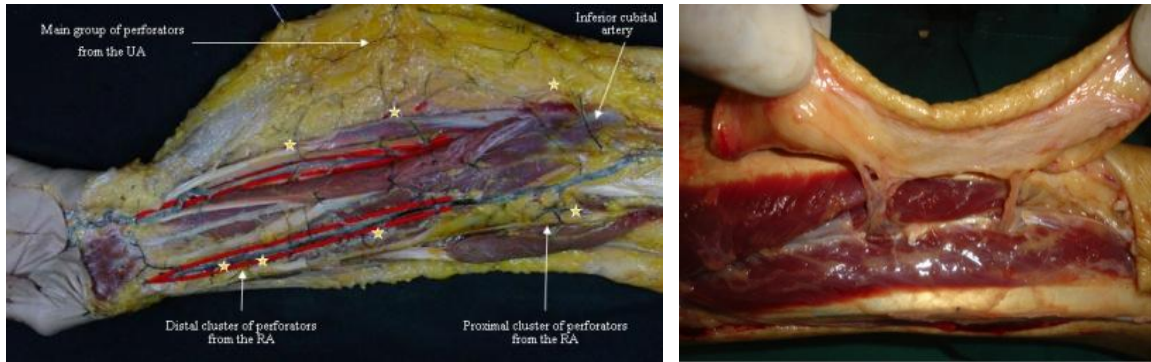


Figure 4 (left): Dissection in a fresh cadaver forearm, after latex injection. The picture shows the distribution of the perforators of RA and UA. The small stars indicate the main perforators of RA and UA.

Figure 5 (right): Dissection in a fresh cadaver forearm. The two main perforators of the RA in the distal cluster can be viewed.

Ulnar Artery

The territory vascularized by the UA extends between the projection of the palmaris longus and the projection of the posterior subcutaneous border of the ulna.

The main group of perforators is found in the distal 2/3 of the forearm, the most important being located most frequently at about 8cm proximal to the pisiform bone (Figure 4). Yu et al have demonstrated that at least 2 or 3 perforators were consistently found in the forearm, on a line connecting the pisiform and the volar aspect of the epicondyle, or slightly ulnar to this line [28]. Sun et al demonstrated that the ulnar artery had two main clusters of perforators in the proximal one-third (7.73cm +/-1.14 distal to the medial epicondyle) and distal one-fourth (4.57cm +/-0.59 proximal to the pisiform bone) of the forearm. Both these clusters emerged from the space between the flexor digitorum superficialis and the flexor carpi ulnaris muscles. In a large series over 27 years, Mathy et Al. have found between 0 and 6 perforators in each forearm. At least one perforator was found in 94% of the cases 3cm within the midpoint from the line joining the pisiform bone and the medial epicondyle, and in 100% of the cases within 6cm within the midpoint of the same line [29].

Posterior Interosseous Artery

The perfusion territory of the PIOA extends in a 5cm wide strip from the lateral epicondyle to the head of the ulna.

There is an average of 5 large clinically relevant perforators arising from the PIOA and providing blood supply to the dorsal aspect of the forearm. These perforators tend to be more proximally located (Fig. 6). The perforators found in the lower third of the dorsal

aspect of the forearm arise from the AIOA rather than the PIOA [30-32]. Angrigiani et al [30] and Hubmer et al [31] have studied the anastomotic network between the AIOA and PIOA and have found that the distal third of the posterior forearm is vascularized by a recurrent dorsal branch of the AIOA.

On the wrist level, the most distal perforators of the PIOA realize anastomoses with the AIOA, the dorsal carpal arch, and the UA [33].

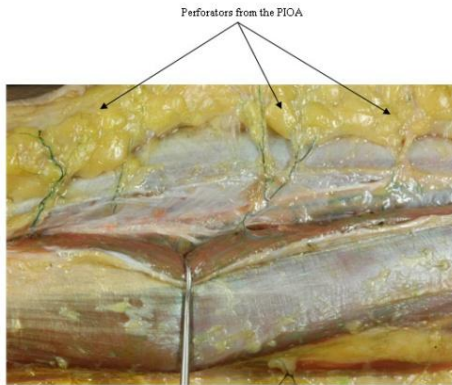


Figure 6: Dissection in a fresh cadaver forearm, after latex injection. The main perforators of the PIOA can be viewed.

Anterior Interosseous Artery

The perfusion territory of the AIOA is represented by the skin over the lower part of extensor pollicis brevis and abductor pollicis longus, and is realized through three perforating branches. The most important of these perforators emerges at the proximal border of the pronator quadratus muscle and supplies the skin over the distal 2/3 of the dorsal aspect of the forearm [34].

As shown by Yousif et al, the perforators emerging from these source arteries can travel either within or in close proximity to the deep fascia or through the subcutaneous tissue [35]. It seems that the main source of the blood supply for the skin remains the subcutaneous arterial network. This was demonstrated by Schaverien and Saint-Cyr in a CT-angiography analysis on fresh cadavers. The authors investigated the perfusion patterns of both the subfascial and suprafascial forearm flaps with computed tomography. The 3D angiographies that were obtained showed no statistically relevant differences between the two techniques, indicating that a suprafascial dissection of the radial forearm flap does not compromise its blood supply [36].

The venous drainage of the skin is realized through one or two venae comitantes accompanying each perforator artery, and which realize a very rich venous plexus draining both into the superficial and deep systems of veins.

Metacarpal Arteries

The first dorsal metacarpal artery (DMA) and the DCA originate directly from the RA before it enters the palm. The second through fifth DMAs emerge subsequently from the

DCA. The first, second and third DMAs are present in over 95% of the cases, whereas the fourth and fifth DMAs appear less consistent [37, 38]. The first through fifth DMAs have a mean diameter of respectively 0.6, 0.8, 0.5, 0.4 and 0.2mm. The DMAs provide four to eight perforators (0.1-0.3mm in diameter) to the skin [38]. The DMAs run distal and pass through to the palmar arterial system at the metacarpal head level. A perforator originates from the junction between these vascular systems [23]. This perforator supplies the dorsal skin of the hand and is known as the perforator from the dorsal communicating branch of the common digital artery (CDA) or Quaba perforator. The blood flow is provided by the anterograde flow from the DMA or retrograde flow from the palmar artery system or dorsal digital arteries. The flaps based on this perforator can cover defects to the distal interphalangeal (DIP) joint. At the level of the proximal half of the first phalanx (P1) of the long fingers, corresponding to the 2nd to 4th web spaces, there are two important anastomoses: (1) at the union of the proximal with the middle third of the P1, between the DMA and the CDA; (2) at the middle of the P1, between the dorsal branch of the CDA and the dorsal branch of the PDA (Fig. 7). Because of the more distal situation of the pivot point, these flaps can reach also the distal phalanx, both dorsal and volar [39].

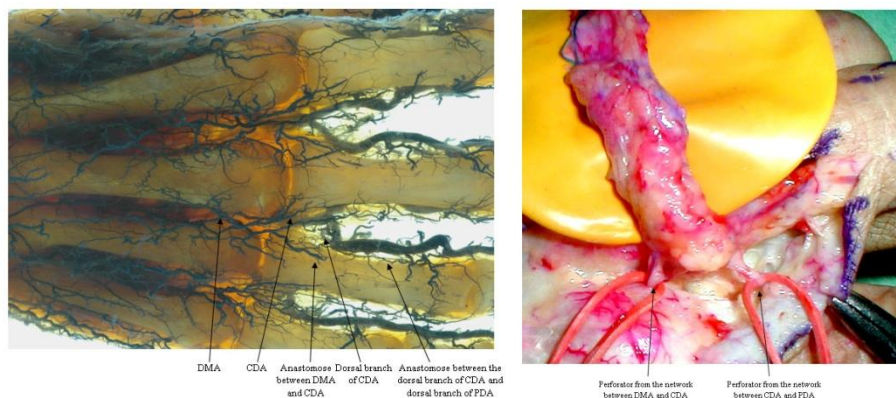


Figure 7: Dorsal metacarpal artery (DMA) and its anastomoses with the digital arteries. Left: Transparency technique applied on fresh cadaver hand specimen with the arterial system injected with latex. Right: Dissection in a fresh cadaver hand showing the above mentioned anastomoses. (CDA - common digital artery; PDA - proper digital artery)

Digital Arteries

The digital arteries give many branches on both lateral and medial aspects of the fingers [40] (Fig. 8). After perforating the thin fascia and subcutaneous tissue, these branches end through multiple arterioles into the subdermal layer. There are very rich anastomoses between these perforators at the level of the lateral and medial midlines of the fingers. The venous drainage is realized through small venules, which connect to the dorsal and palmar cutaneous venous systems in the subcutaneous tissue. Small branches of the digital nerves, together with their rich vascular network, are also present and very close to the vascular network. In conclusion, the blood supply of the dorsal aspect of the long fingers is realized as follows: (1) through perforators from the

DMA at the level of the web space and metacarpal head; (2) through dorsal digital arteries emerging from the DMA in the proximal half of the P1; (3) through branches of the PDA; (4) through 1-2 small branches of the PDA at the level of the middle phalanx; (5) through a few arches originating in the PDA at the level of the distal phalanx.

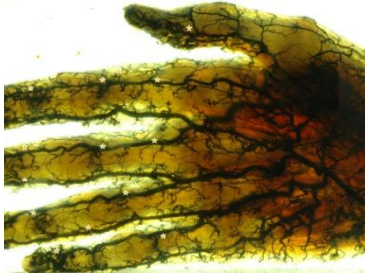


Figure 8: Transparentation technique applied on fresh cadaver hand specimen with the arterial system injected with latex. The small stars indicate some of the perforators of the PDAs.

Flap designs and harvesting techniques of propeller perforator flaps in the forearm and hand

Design of the flap

The preoperative planning of perforator flaps by using diverse imaging techniques and hand-held Doppler is not very useful in the forearm because of the proximity of the main source arteries as well as their superficial location within the forearm. It is also relatively difficult to do this in the hand and fingers [9, 10, 26]. This is why, generally, the identification and isolation of the perforators is done intraoperatively through a careful dissection and consideration of the defect needs.

Harvesting technique (Fig. 9)

Only one edge of the potential flap is incised at the beginning. It is better to place this incision so that it is possible to be the limit of a second flap option, if a suitable perforator is not found. The incision can be either supra or subfascial. The dissection is performed under magnification and all the identified perforators are preserved. If more adjacent perforators of similar calibre are found, it is better to keep them until the releasing of the tourniquet, and decide on which will be used as the vascular pedicle of the flap only after clamping them alternately. The definitive design of the flap is accomplished according to the chosen perforator, and its location, size, number of venae comitantes, course and orientation. The long axis of the flap should be orientated in the long axis of the segment. The length of the flap should be greater than the distance between the perforator and the most distant edge of the defect adding 1-2cm in the forearm and 0.5-1cm in the hand and fingers. Similar, to the width of the defect is added 0.5-1cm to allow closure without tension. After enlarging the perforator foramen, the perforator is cleared of all muscular branches and fascial strands for at least 2cm in the forearm and 1cm in the hand and fingers, but no longer than needed for an optimal

rotation of the flap. It is not necessary to completely skeletonize the perforator pedicle, but it is better, especially in the fingers, to retain a small cuff of tissue around it to avoid the vessel spasm. After that, the incision around the flap is completed, but the flap should be rotated only after releasing the tourniquet and observing the pulsation of the perforator. If pulsation is not yet present, it is better to maintain the flap in its original position for 10-15 minutes to allow the spasm to disappear. Attention should be paid to the correct rotational direction to avoid kinking of the perforator. Closure of the donor site under tension should be avoided to prevent reduction of the flap's blood supply by compression of the source vessel and swelling of the distal segment. If closure by direct suture is not possible, the use of a FSTG is indicated.

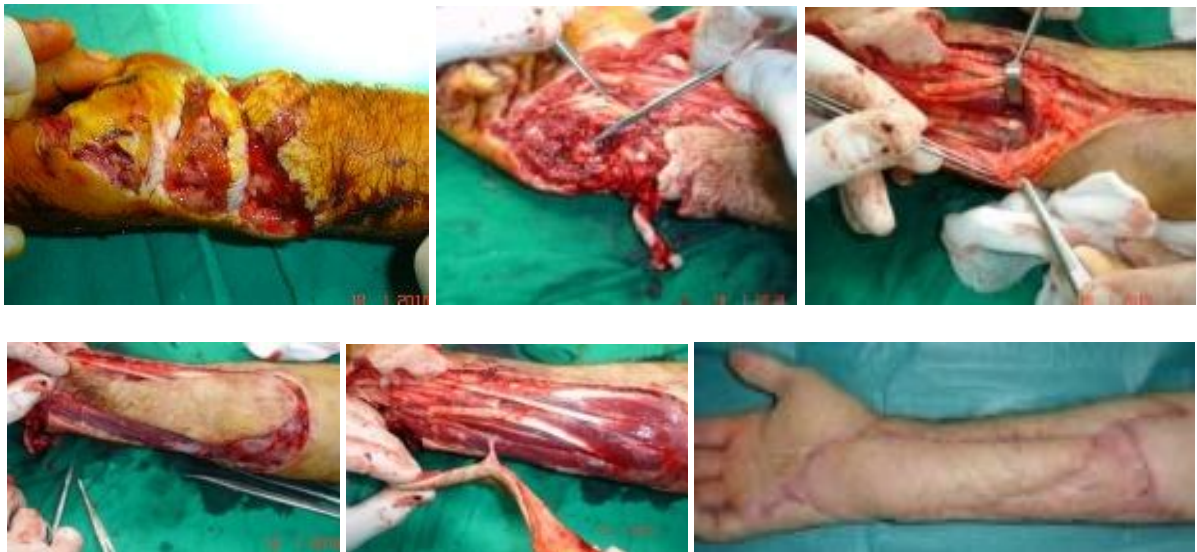

Figure 9: Complex wound in the distal forearm and hypothenar region - technique of harvesting of a propeller perforator flap – A) Preoperative aspect; B) Remaining defect after debridement; C) Incision of only one edge of the potential flap and identification of a perforator of the ulnar artery through careful microsurgical dissection; D) After the final design of the ulnar artery propeller perforator flap, according to the location of the chosen perforator, the flap is completely incised; E) The harvested flap will be rotated 180 degrees to cover the defect; F) Postoperative result after 6 months.

Indications for propeller perforator flaps in the forearm and hand

The main advantages of propeller perforator flaps recommend them as a valuable option in the reconstruction armamentarium. The surgical procedure is relatively easy and less time consuming, which offers a lot of benefits to the elderly, multiple injured patients, or to those with a compromised general health status. The reconstruction with propeller perforator flaps replaces like-with-like by using tissues of similar texture, thickness, pliability, and color. Moreover, this method avoids the complexity, the multiple surgical sites and the high costs associated with free flaps and microsurgery. Preserving the source artery and the underlying muscle, the propeller perforator flaps reduce drastically the donor site morbidity. For flaps with a width less than 4-5cm the donor site can be closed by direct suture, but even bigger defects can be partially directly

sutured. The cosmetic appearance of the donor site can represent a significant drawback, but generally this one can be easily tolerated in very complex defects. A potential disadvantage can be related to the location of the perforator within the zone of injury, but generally this fact does not interfere with the viability of the flaps.

The main indication for propeller perforator flaps is the coverage of small to medium size defects, but sometimes their dimensions could be larger. This happens in cases in which a perforator vessel cannot be found close to the defect. We harvested some larger flaps based on a single perforator, and the largest one in the forearm in our experience was an ulnar artery perforator flap of 28X6cm (170sqcm). The explanation for survival of such big flaps can be found in the perforasome concept of Saint-Cyr et al [4], according to which the hyperperfusion in a perforator allows the capture of multiple adjacent perforasomes through direct and indirect linking vessels.

The radial artery propeller perforator flap (RAPPF) is very thin and pliable, and can be harvested as chimeric flap including bone, muscle, tendons, but can also be innervated and used as a sensate flap. Based on perforators from the proximal group, the flap is very useful for coverage of elbow defects. The flaps based on distal perforators are very useful for coverage of hand defects. The RAPPF can also be used as an adipofascial perforator flap, very useful in the coverage of volar and dorsal hand wounds, treatment of recurrent de Quervain's tendonitis, flexor tendon sheath reconstruction and wrist and median nerve padding. The use in such a way avoids the bulkiness observed after using a fasciocutaneous flap and ameliorates very much the donor site appearance. The donor site morbidity associated with the RAPPF when used as fasciocutaneous flap, can sometimes surpass its advantages. Even if from functional point of view the morbidity can be minimized by harvesting the flap in a suprafascial plane, there still remain some drawbacks from the cosmetic point of view.

The ulnar artery propeller perforator flap (UAPPF) is also very thin and pliable, but is thinner and hairless if compared with the RAPPF (Fig. 9). It can be also designed as a chimeric flap including bone, muscle and tendon. It seems that because all these facts, but also due to the lesser exposure of the tendons, the UAPPF leads to better functional and cosmetic outcomes [28]. The flap is very useful in the coverage of the dorsal aspect of the hand, of the hypothenar area and of the volar aspect of the wrist.

Both the posterior interosseous artery propeller perforator flap (PIOAPPF) and the anterior interosseous artery propeller perforator flap (AIOAPPF) have a structure very close to the hand skin texture, which allows reconstructions of the dorsal hand with good outcomes, both functional and cosmetic. [32]. The PIOAPPF can be also harvested based on proximal perforators, finding its indication in coverage of elbow defects.

The dorsal metacarpal propeller perforator flap finds its indication in the coverage of small defects of the dorsal aspect of the hand and fingers to the DIP joint, but also for more extensive defects of the fingers up to the distal phalanx, both volar and dorsal, when they are harvested based on commissural perforators – commissural propeller perforator flap (Fig. 10).

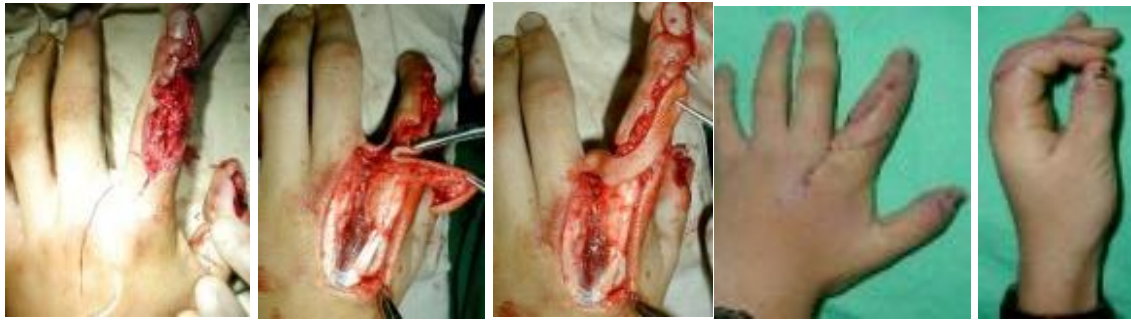

Figure 10: Complex defect of the dorsoradial defect of the index finger: A) Preoperative defect and design of a propeller perforator flap based on perforators form the anastomose between the dorsal branch of the CDA and the dorsal branch of the PDA; B) The flap is harvested based on the above mentioned perforator. Because the very small caliber of the perforator and in the attempt to avoid the spasm, a small cuff of tissue is preserved around it; C) Rotation of the flap for 180 degrees to cover the defect; D) and E) Postoperative aspect after 2 months.

The digital artery propeller perforator flap (DAPPF) was first described by Koshima et al for fingertip reconstruction [40], but the flap can be successfully used also for covering more proximal defects on both palmar and dorsal aspect of the fingers (Fig. 11, Fig. 12). It can be used also as sensate flap in covering the palmar aspect of the fingers.

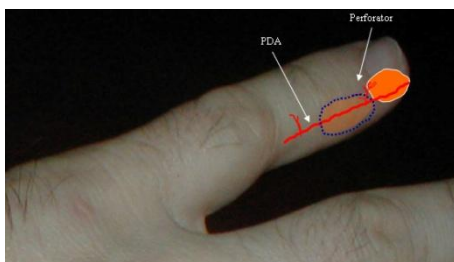


Figure 11: Schematic representation of a digital artery propeller perforator flap (PDA – proper digital artery)

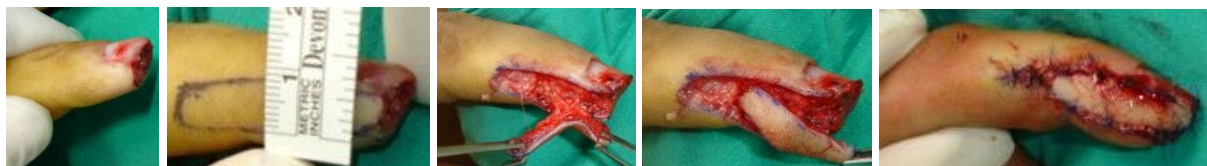

Figure 12: Fingertip amputation: A) Preoperative; B) Design of a propeller flap based on a perforator originating in the PDA. The width of the flap (0.8cm) allows donor site closure by direct suture; C) The harvested flap. A small cuff of tissue is preserved around the perforator; D) Rotation of the flap for 180 degrees; E) Postoperative - donor site closed by direct suture.

For a width of the flap less than 0.8cm the donor site can be directly closed, but for larger flaps a free skin graft is needed. To avoid this disadvantage, the flap can be designed as a bi-lobed pedicled flap based on the same perforator vessels, which need not be identified (Fig. 13, Fig. 14). In this case, the first lobe represents the flap which will cover the defect, and is designed transversely or slightly obliquely; the second flap, which will cover the donor site of the first flap, is designed longitudinally and has a maximum width of 2/3 from the width of the first one. The donor site of the second flap can be directly sutured.

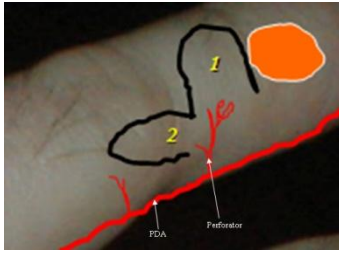


Figure 13: Schematic representation of a bi-lobed pedicled perforator flap: 1 - first lobe of the flap, which will be rotated into the defect; 2 – second lobe of the flap, which will be rotated into the remaining defect (PDA - proper digital artery)

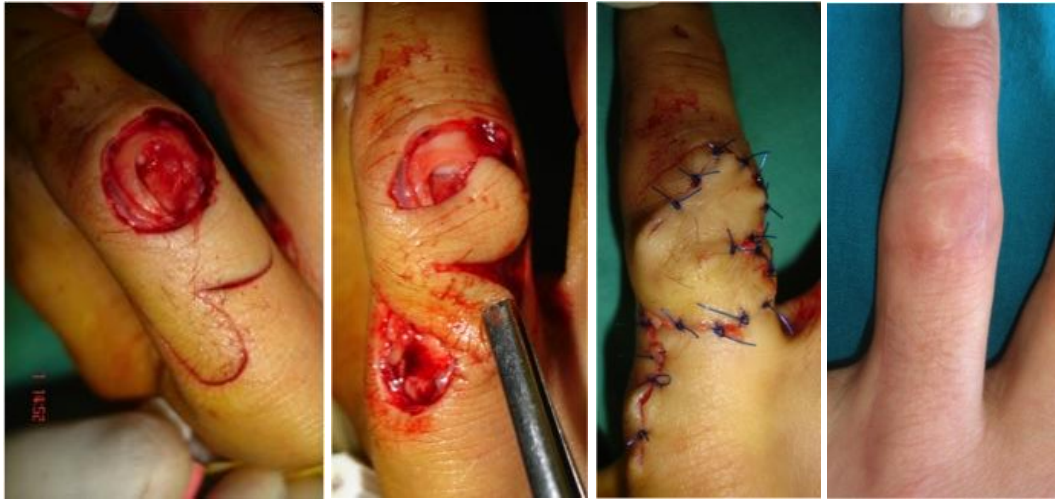

Figure 14: Defect over the dorsal aspect of the proximal interphalangeal joint of the index finger, including skin and extensor tendon: A) Preoperative aspect and design of the bi-lobed flap; B) The bi-lobed flap harvested; the first lobe includes also a small strip harvested from the proximal part of the extensor tendon; C) Immediate postoperative aspect; the donor site of the second flap closed by direct suture; D) Postoperative aspect one year after surgery

Complications

The most common complication of propeller perforator flaps is represented by venous congestion of the tip or of the entire flap, and is due to the insufficient flow in the perforator pedicle. This happens either because of inadequate selection of the perforator, or due to its insufficient dissection and mobilisation, especially around the vein. If venous congestion is observed intra-operatively, venous supercharging of the flap can be done by performing a microvascular venous anastomosis. In instances of signs of ischemia, derotation of the flap to its original position can be attempted. In instances of vascular problems appearing after surgery, some flaps can be saved by removing the stitches, by doing small punctures or incisions and applying local heparinization, or by using leeches.

If compared with free flaps, the loss of a propeller perforator flap, involves generally only partial thickness of the flap. If a free flap is lost, everything is lost, while generally in a propeller perforator flap only the superficial part is lost. This means that the flap has done its job of covering the denuded anatomical elements, because after debridement granulation of the wound is very fast and allows skin grafting.

To conclude, the presence of numerous perforator vessels supplying the forearm, hand and fingers makes rational and reliable the harvesting of local perforator flaps in order to cover small and medium size defects. The functional and aesthetic outcome is more than acceptable, but their use needs further research especially regarding the real possible dimensions of these kinds of flaps.

References

1. Taylor GI, Palmer JH. The vascular territories (angiosomes) of the body: Experimental study and clinical applications. *Br J Plast Surg* 1987;40:113-41.
2. Manchot C. The cutaneous arteries of the human body. New York: Springer-Verlag; 1983
3. Salmon M. In: Taylor GI, Tempest M, editors. Arteries of the skin. London: Churchill Livingstone; 1988
4. Saint-Cyr M, Wong C, Schaverien M, et al. Perforasome theory: Vascular anatomy and clinical implications. *Plast Reconstr Surg* 2009;124:1529-44
5. Rubino C, Coscia V, Cavazzuti AM, et al. Haemodynamic enhancement in perforator flaps: the inversion phenomenon and its clinical significance: A study of the relation of blood velocity and flow between pedicle and perforator vessels in perforator flaps. *J Plast Reconstr Aesthet Surg* 2006;59:636-43
6. Kroll SS, Rosenfield L. Perforator-based flaps for low posterior midline defects. *Plast Reconstr Surg* 1988;81:561-6
7. Koshima I, Soeda S. Inferior epigastric artery skin flap without rectus abdominis muscle. *Br J Plast Surg* 1989;42:645-8
8. Lecours C, Saint-Cyr M, Wong C, et al. Freestyle pedicle perforator flaps: Clinical results and vascular anatomy. *Plast Reconstr Surg* 2010;126:1589-603
9. Georgescu AV, Matei I, Ardelean F, et al. Microsurgical nonmicrovascular flaps in forearm and hand reconstruction. *Microsurgery* 2007; 27: 384-94
10. Matei I, Georgescu AV, Chiroiu B, et al. Harvesting of forearm perforator flaps based on intraoperative vascular exploration: Clinical experiences and literature review. *Microsurgery* 2008;28:321-30
11. Lee BT, Lin SJ, Bar-Meir ED, et al. Pedicled perforator flaps: A new principle in reconstructive surgery. *Plast Reconstr Surg* 2010; 125:201-8
12. Chang YT, Wang XF, Zhou ZF, et al. The reversed forearm fasciocutaneous flap in

- hand reconstruction: 10 successful cases. *Chin J Plast Surg Burns* 1988; 4:41-49
13. Hyakusoku H, Yamamoto T, Fumiiri M. The propeller flap method. *Br J Plast Surg* 1991;44:53-4
 14. Hallock GG. The propeller flap version of the adductor muscle perforator flap for coverage of ischial or trochanteric pressure sores. *Ann Plast Surg* 2006;56:540-2
 15. Pignatti M, Ogawa R, Hallock GG, et al. The “Tokyo” consensus on propeller flaps. *Plast Reconstr Surg* 2011;127:716-22
 16. McCraw JB, Myers B, Shanklin KD. The value of fluorescein in predicting the viability of arterialized flaps. *Plast Reconstr Surg* 1977;60:710-9
 17. Morykwas MJ, Hills H, Argenta LC. The safety of intravenous fluorescein administration. *Ann Plast Surg* 1991;26:551-3
 18. Eren S, Rubben A, Krein R, et al. Assessment of microcirculation of an axial skin flap using indocyanine green fluorescence angiography. *Plast Reconstr Surg* 1995;96:1636-49
 19. Holm C, Mayr M, Hofter E, et al. Intraoperative evaluation of skin-flap viability using laser-induced fluorescence of indocyanine green. *Br J Plast Surg* 2002;55:635-44
 20. Matsui A, Lee BT, Winer JH, et al. Real-time intraoperative near-infrared fluorescence angiography for perforator identification and flap design. *Plast Reconstr Surg* 2009;123:125e-127e
 21. Kanellakos GW, Yang D, Morris SF. Cutaneous vasculature of the forearm. *Ann Plast Surg* 2003; 50:387-92
 22. Maruyama Y. The reverse dorsal metacarpal flap. *Br J Plast Surg* 1990; 43:24-7
 23. Quaba AA, Davison PM. The distally-based dorsal hand flap. *Br J Plast Surg* 1990; 43:28-39
 24. Koshima I, Urushibara K, Fukuda N, et al. Digital artery perforator flaps for fingertip reconstructions. *Plast Reconstr Surg* 2006; 118: 1579-84
 25. Cormack GC, Lamberty BG. Fasciocutaneous vessels: Their distribution on the trunk and limbs, and their clinical application in tissue transfer. *Anat Clin* 1984; 6:121-31
 26. Saint-Cyr M, Mujadzic M, Wong C, et al. The Radial Artery Pedicle Perforator Flap: Vascular Analysis and Clinical Implications. *Plast Reconstr Surg* 2010; 125:1469-78
 27. Koshima I, Moriguchi T, Etoh H, et al. The radial artery perforator based adipofascial flap for dorsal hand coverage. *Ann Plast Surg* 1995; 35:474-479

28. Yu P, Chang EI, Selber JC, Hanasono MM. Perforator patterns of the ulnar artery perforator flap. *Plast Reconstr Surg* 2012; 129:213-20
29. Mathy JA, Moaveni Z, Tan ST. Vascular anatomy of the ulnar artery perforator flap. *Plast Reconstr Surg* 2013; 131:115e-6e
30. Angrigiani C, Grilli D, Dominikow D, et al. Posterior interosseous reverse forearm flap: experience with 80 consecutive cases. *Plast Reconstr Surg* 1993. 92:285-93
31. Hubmer MG, Fasching T, Haas F, et al. The posterior interosseous artery in the distal part of the forearm. Is the term "recurrent branch of the anterior interosseous artery" justified? *Br J Plast Surg*; 2004; 57:638-44
32. Mei J, Morris SF, Ji W, et al. An anatomic study of the dorsal forearm perforator flaps. *Surg Radiol Anat* 2013; 35:695-700
33. Landi A, Luchetti R, Soragni O, et al. The distally based interosseous island flap for the coverage of skin loss of the hand. *Ann Plast Surg* 1991; 27: 527-36
34. Syed SA, Zahir KS, Zink JR, et al. Distal dorsal forearm flap. *Ann Plast Surg* 1997; 38:396-403
35. Yousif NJ, Ye Z, Grunert BK, et al. Analysis of the distribution of cutaneous perforators in cutaneous flaps. *Plast Reconstr Surg* 1998; 101:72-84
36. Schaverien, M, Saint-Cyr M. Suprafascial compared with subfascial harvest of the radial forearm flap: an anatomic study. *J Hand Surg (Am)* 2008; 33:97-101
37. Bailey SH, Andry D, Saint-Cyr M. The dorsal metacarpal artery perforator flap: a case report utilizing a quaba flap harvested from a previously skin-grafted area for dorsal 5th digit coverage. *Hand (N Y)*, 2010. 5(3): p. 322-5.
38. Omokawa S, Tanaka Y, Ryu J, et al. The anatomical basis for reverse first to fifth dorsal metacarpal arterial flaps. *J Hand Surg (Br)* 2005; 30:40-4
39. Bakhach J, Demiri E, Conde A, et al. Le lambeau métacarpien dorsal à pédicule rétrograde étendu. Etude anatomique et à propos de 22 cas cliniques. *Ann Chir Plast Esthet* 1999; 44:185–193
40. Koshima I, Urushibara K, Fukuda N, et al. Digital artery perforator flaps for fingertip reconstructions. *Plast Reconstr Surg* 2006; 118: 1579-84